



Published in final edited form as:

*Neuroendocrinology*. 2016 ; 103(2): 153–171. doi:10.1159/000443171.

## Consensus guidelines update for the management of functional p-NETs (F-p-NETs) and non-functional p-NETs (NF-p-NETs)

M Falconi<sup>a,\*</sup>, B Eriksson<sup>b,\*</sup>, G Kaltsas<sup>c,\*</sup>, DK Bartsch<sup>d</sup>, J Capdevila<sup>e</sup>, M Caplin<sup>f</sup>, B Kos-Kudla<sup>g</sup>, D Kwekkeboom<sup>h</sup>, G Rindi<sup>i</sup>, G Klöppel<sup>j</sup>, N Reed<sup>k</sup>, R Kianmanesh<sup>l</sup>, RT Jensen<sup>m</sup>, and all other Vienna Consensus Conference participants<sup>n</sup>

<sup>a</sup>Department of Surgery, San Raffaele Hospital, Università Vita e Salute, Milan, Italy <sup>b</sup>Department of Endocrine Oncology, University Hospital Uppsala, Sweden <sup>c</sup>Department of Pathophysiology, Div Endocrinology, National University of Athens, Greece <sup>d</sup>Department of Surgery, Philipps University, Marburg, Germany <sup>e</sup>Vall d'Hebron University Hospital, Vall d'Hebron Institute of Oncology (VHIO), Barcelona, Spain <sup>f</sup>Neuroendocrine Tumour Unit, Royal Free Hospital, London, UK <sup>g</sup>Department of Endocrinology, Medical University of Silesia, Katowice, Poland <sup>h</sup>Department of Internal Medicine, Div Nuclear Medicine, Erasmus MC, Rotterdam, Netherlands <sup>i</sup>Institute of Anatomic Pathology, Policlinico A. Gemelli, Università Cattolica del Sacro Cuore, Rome, Italy <sup>j</sup>Institute of Pathology, Technische Universität München, Munich, Germany <sup>k</sup>Beatson Oncology Centre, Gartnavel General Hospital, Glasgow, UK <sup>l</sup>Department of Surgery, CHU Robert Debré Reims, France <sup>m</sup>Digestive Diseases Branch, NIH, Bethesda, Md. USA

Prof. Massimo Falconi, Ospedale San Raffaele, Milano (Italy), falconi.massimo@hsr.it.

<sup>n</sup>**Alphabetically:** Anlauf, M (Institut für Pathologie und Zytologie, St. Vincenz Krankenhaus); Baudin, E (Institut Gustave Roussy, Villejuif, France); Costa, F (Centro de Oncologia, Hospital Sírio Libanês, Sao Paulo, Brazil); Cwikla, J (University of Warmia and Mazury, Olsztyn, Poland); De Herder, WW (Department of Internal Medicine, Div. Endocrinology, Erasmus MC, Rotterdam, Netherlands); Delle Fave, GF (Department of Digestive and Liver Disease, Ospedale Sant' Andrea, Rome, Italy); Ferolla, P (NET Center, Umbria Regional Cancer Network, Università degli Studi di Perugia, Perugia); Ferone, D (Department of Endocrine & Metabolic Sciences (DIMI), University of Genova, Italy); Garcia-Carbonero, R (Medical Oncology Department, Hospital Universitario Doce de Octubre, Madrid, Spain); Gross, D (Department of Endocrinology & Metabolism, Hadassah University Hospital, Mevasseret Tsion, Israel); Ito, T (Pancreatic Diseases Branch, Kyushu University Hospital, Japan); Kelestimur, F (Department of Endocrinology, Erciyes University Medical School, Kayseri, Turkey); Knigge, U (Neuroendocrine Tumor Center of Excellence, Rigshospitalet, Copenhagen University Hospital, Denmark); Krenning, E (Department of Internal Medicine, Div Nuclear Medicine, Erasmus MC, Rotterdam, Netherlands); Niederle, B (Department of Surgery, Medical University of Vienna, Austria); Öberg, K (Department of Medical Sciences, Endocrine Oncology Unit, University Hospital, Uppsala, Sweden); O'Connor, J (Department of Clinical Oncology, Institute Alexander Fleming, Buenos Aires, Argentina); O'Toole, D (NET Centre St. Vincent's University and DOCM St. James Hospital & Trinity College, Dublin, Ireland); Pape, U-F (Department of Hepatology and Gastroenterology, Campus Virchow Klinikum, Charité Universitätsmedizin Berlin, Germany); Pascher, A (Department of Visceral & Transplant Surgery, Charité, Campus Virchow Clinic, Berlin, Germany); Pavel, M (Department of Hepatology and Gastroenterology, Campus Virchow Klinikum, Charité Universitätsmedizin Berlin, Germany); Perren, A (Institute of Pathology, University of Bern, Bern, Switzerland); Ramage, J (Gastroenterology Department Hampshire Hospitals NHS Trust, Hampshire, UK); Raymond, E (Oncologie Médicale, Hôpitaux universitaires Paris Nord Val de Seine, Paris, France); Ruzniewski, P (Department of Gastroenterology, Beaujon Hospital, Clichy, France); Sedlackova, E (Department of Oncology of the First Faculty of Medicine and General Teaching Hospital, Prague, Czech Republic); Sorbye, H (Department of Oncology Haukeland University Hospital, Bergen, Norway); Sundin, A (Department of Radiology, Section for Molecular Imaging, Uppsala University Hospital, Uppsala, Sweden); Taal, B (Netherlands Cancer Centre, Lijnden, Netherlands); Toumpanakis, C (Neuroendocrine Tumour Unit, Royal Free Hospital, London, United Kingdom); Weber, W (Department of Radiology, Memorial Sloan Kettering Cancer Center, New York, USA); Wiedenmann, B (Department of Hepatology and Gastroenterology, Campus Virchow Klinikum, Charité Universitätsmedizin Berlin, Germany); Zheng-Pei, Z (Department of Endocrinology, Peking Union Medical College Hospital)

\* denotes co-first authors

## Introduction to F-p-NETs and NF-p-NETs

Only advances that occurred from 2011–2014 that either strengthen the previous 2011 guidelines [1;2] or lead to changes or additional guidelines are reviewed here. Advances and modifications in the treatment of advanced metastatic disease is only briefly dealt with here as it is covered in a separate chapter, similar to the 2011 guideline format [3]. The format used here is the same as used in the 2011 guidelines with page references to the appropriate section inserted [1;2] and this document is meant as a supplement to these guidelines and does not reiterate all of the points made in the previous guidelines, only changes, supporting findings or modifications of the 2011 guidelines are thus covered here.

As in the previous F-p-NET guidelines [1], the F-p-NETs will be considered in three groups: the more frequent gastrinomas and insulinomas considered independently and all the rare functional p-NETs (RFTs) considered together and as a separate category (Annex 1 and Table 1).

Most p-NETs occur as sporadic tumors (non-inherited), although a variable proportion for the different F-p-NETs occur as part of an inherited syndrome. MEN1 remains the most important inherited condition responsible for 20–30% of gastrinoma, <5% of insulinomas or RFTs [11–14]; and uncommon causes of inherited p-NETs include von Hippel Lindau disease (VHL), von Recklinghausen's syndrome (neurofibromatosis 1), and tuberous sclerosis [11;12]. In each of the latter inherited disorders, the patients only rarely develop a F-p-NETs, with 10–17% of VHL patients developing NF-p-NETs, <10% of NF-1 patients developing a p-NET, which is almost always a somatostatinoma of the duodenum, which is rarely functional, and patients with tuberous sclerosis only rarely (<1%) developing a F-p-NET or NF-p-NET [11]. Other rarer syndrome with a possible genetic link is discussed in Annex 1.

## Epidemiology and clinico-pathological features of F-p-NETs and NF-p-NETs

The frequency of F-p-NETs, similar to NF-p-NETs, and all GI-NETS [18;19] continues to be reported to be increasing in a number of countries [19–23]. In some recent series, between 60% and 90% of p-NETs are non-functional, which are generally diagnosed at more advanced stages because of their relatively indolent nature and slow growth causing a delay in onset of symptoms. However there is also an exponential increase of incidental diagnoses of NF-p-NETs which are becoming frequent with the widespread use of high-quality imaging techniques [24–26].

In general the rare and very rare F-p-NETs listed in Table have sufficient numbers of cases or sufficient descriptions of small numbers of cases to verify that they should be considered as established F-p-NET syndromes [4;27]. A possible exception to this is the case of somatostatinomas. Recently the actual existence of a distinct clinical somatostatinoma (SSoma) syndrome has been questioned because in one extensive review of cases, none of the 46 patients with pathologically diagnosed SSomas, nor any of 821 other p-NET cases reviewed, had the full features of the proposed SSoma clinical syndrome [28].

A small percentage of patients with gastric acid hypersecretion and clinical features of ZES are found to have normal fasting serum gastrin levels and negative secretin tests [29–31], and in light of the features of the patient recently described with a CCKoma [7], these patients should have plasma CCK levels assessed. This may be difficult at present because only a few groups have proven assays, and recent studies demonstrate that many commercial laboratories use poorly characterized antibodies even for such frequent assays as the assessment of serum gastrin levels [32;33].

## Prognosis and survival in sporadic F-p-NETs and NF-p-NETs

Numerous studies have described molecular changes in p-NETs that correlate with prognosis, in most cases not distinguishing the type of p-NET syndrome. This will be considered in a later section on the histopathology and genetics of functional p-NETs. In addition to the prognostic factors described in the previous guidelines [1] recent papers have described further prognostic factors. These include:

- a. the demonstration that the presence of calcifications on CT scanning preoperatively in patients with p-NETs (occur in 16%) [34] correlates with the grade and the presence of lymph node metastases in well-differentiated p-NETs;
- b. the demonstration that the extent of liver metastases either unilobar, bilobar or the presence of extra abdominal metastases is an important predictors of survival independent of the tumor grading (Ki-67 index) [35]; and
- c. most patients with advanced p-NETs progress over time and the best prognosticator for progression was the Ki-67 index [36];
- d. A number of studies [37;38;47–52] now report in patients with p-NETs that the presence of lymph nodes and number in some studies, have important prognostic value. These results support the recommendation that systematic removal of lymph nodes in the peritumoral area should be part of any p-NET operation. However in addition to In the case of lymph node involvement both the nodal positive status on its own, the number of lymph nodes involved, as well as the ratio between lymph node positive and total examined lymph nodes are important predictors of recurrence after surgery [37;38]. This will be further discussed in the later therapy section;
- e. In one study the absence of symptoms was associated with a significantly better outcome despite the tumour stage [36]. Since the incidental diagnoses of p-NETs is becoming more frequent, especially in the case of NF-p-NETs, with the widespread use of high-quality imaging techniques this figure can have an impact on therapeutic choice [39;40].

Numerous recent studies have established the importance of the different classification and grading systems for p-NETs and other NETs that have been proposed (WHO2010, ENETs, AJCC/UICC)[19;41;42]. In numerous studies [41;43–46] both the classification and grading have prognostic value, in most cases as an independent variable on multivariate analysis, and therefore it is essential not only for the proper treatment strategy, but also for the prognostic

value, that in all F-p-NET patients, proper staging, tumor classification and grading should be performed [19;41;42].

As will be discussed in the later histopathology section, a number of molecular changes have been described which, although still not used generally clinically, have prognostic significance such as chromosome instability as a consequence of loss of some genes (DAXX or ATRX) has been shown to correlate with a worse survival [53].

### **Prognosis and survival in F-p-NET within MEN1**

As stated in this section of the 2011 guidelines [1] the current prognosis of MEN1 patients with p-NETs remains unclear. This is in large part because of the marked effectiveness of treatment for F-p-NETs within MEN1 (40–60% ZES, 20–30% insulinomas <5% remaining RFTs)[11;12;14]. Prior to development of effective medical therapies, gastric acid hypersecretion due to the ZES, was the main cause of death in MEN1 patients in most series, whereas at present, it can be controlled in all patients and is no longer a cause of death [11;12;31;54]. Furthermore, renal failure due to uncontrolled hyperparathyroidism, and hormone excess-states due to pituitary tumours and other F-p-NET syndromes is no longer a frequent cause of death in MEN1 patients [11;12;55]. Recently, important information on the natural history and prognostic factors in these patients was provided by large prospective NIH study of MEN1 patients with ZES (MEN1/ZES)(n=106) [12] followed for a mean of 24.5 years, and the results compared to a pooled literature group of 227 MEN1 patients with p-NETs, who did not die of gastric acid hypersecretion, and to 1386 MEN1 in various large MEN1 series (60% had p-NET). In this study, none of the NIH patients died from gastric hypersecretion and in both the NIH patients and pooled literature series, 2/3 of the patients died from an MEN1 related cause and in 40% the cause of death was due to the p-NET, which was the main cause of death. The second most frequent cause of mortality in MEN1 is due to thymic carcinoids, which occur primarily in men (>90%) and are very aggressive tumors [12;14;55–57]. In this study [12] the non MEN1-related causes of death were reported for the first time with the relative order being cardiovascular disease, other non MEN1 malignancies (mainly lung) and cerebrovascular disease. Important prognostic factors found in this study [12] include the presence of thymic carcinoids, presence of liver or distant metastases, aggressive p-NET growth, large p-NETs, development of new lesions during follow-up, high levels of tumor markers such as gastrin and the development of other functional p-NET syndromes.

### **Clinical presentation of F-p-NETs**

The clinical features of patients with gastrinoma and ZES and insulinoma have been covered in detail in the previous guidelines (1). Literature updates included a recent study [58] reporting that 81% of patients with ZES due to duodenal tumors (60–95% of ZES patients) had a long-term history of high alcohol use (>50 g/day) and proposed this may be a risk factor for ZES.

Patients with insulinomas characteristically develop symptoms while fasting or during exercise, however some patients (up to 18%) develop symptoms post-prandially that may be the only symptoms [59–61]. Others have found that with the new guidelines for 72 hour fast

(glucose < 55 mg/dl and insulin < 3  $\mu$ U/ml), in the absence of hypoglycemia an insulinoma is not excluded as patients may present with postprandial hypoglycemia revealed following an OGTT. In a mono-institutional study 18% of patients complained of postprandial symptoms and 21% had previously been affected by diabetes type 2 or impaired glucose tolerance [59]. These data support previous findings that a subset of patients with insulinomas may be diagnosed on the basis of an altered insulin secretory pattern during OGTT inducing hypoglycemia rather than the classical 72 hour fast.

## Diagnosis of F-p-NETs and NF-p-NETs

**Diagnosis of ZES-General (p.102-3[1]) (Figure 1)**—Numerous publications support the conclusion that the diagnosis of ZES is becoming more difficult, [31;33;62–66]. This is occurring because of the increasing unreliability of commercial gastrin assays in many widely used commercial laboratories [32;33]; because of the lack of availability of secretin used to perform secretin provocative tests [67;68] and the widespread use of PPIs [62–64;69]. The unreliability of some commercial gastrin assays can be circumvented by either using a reliable laboratory identified in recent publications [32;33], or by consulting a centre of excellence in the diagnosis of ZES [32;33;62]. The lack of secretin can be a major problem in some patients because 60% of ZES patients present with fasting serum gastrin levels <10-fold the upper limit of normal and with a gastric pH<2, and these features can overlap with number of other conditions. Indeed, up to 40% of these will not have an identifiable gastrinoma, necessitating a secretin test [29;30;62;65;68;70]. Recently a glucagon provocative test with established criteria for positivity has been proposed as a substitute if secretin is not available [67], however with limited data and unclear sensitivity and specificity. The widespread use of PPIs is a major problem for the diagnosis of ZES because these drugs have an extended duration of action (up to one week), they cause hypergastrinemia in 80–100% of normal subjects, and thus can confound the diagnosis [31;62;64;65;69]. Furthermore, if PPIs are abruptly stopped in a true ZES patient, acid-peptic complications can rapidly develop [63;66], and therefore some expert groups recently have recommended that the diagnosis of ZES should be established without stopping the PPIs or by attempting to taper the dose. Unfortunately, as suggested in a number of recent papers [4;31;62;64], in most patients the diagnosis cannot be easily established without interruption of PPIs. Furthermore, a secretin test cannot be used while a patient is taking PPIs because it can result in a false positive test [68]. Other tumor markers such serum chromogranin A have found not to be reliable in the diagnosis of patients with ZES as up to 30% have normal plasma CgA levels [71]. PPIs also lead to increased CgA levels on their own. It therefore is recommend that if the diagnosis (see below) is unclear (fasting serum gastrin <10x increased, gastric pH<2, no tumor imaged), that the patient be referred to a center of excellence and if the latter is not possible PPIs withdrawal should be cautiously performed (asymptomatic patient with no active acid-peptic disease or damage) and with adequate cover by H2 blockers and careful patient monitoring [4;31;62;64] (in-patient setting or daily checks on an outpatient basis).

### Minimum consensus statement on diagnosis: Gastrinoma and ZES: Biochemistry/Laboratory studies

The diagnosis of ZES requires demonstration of an inappropriately elevated fasting serum gastrin (FSG) level in the presence of hypergastrinemia when gastric acid secretion is present. This is best accomplished by establishing hypergastrinemia when the gastric pH is  $<2$  [1;29;62;65;72]. Hypergastrinemia due to a non ZES cause, particularly hypo- or achlorhydria secondary to other conditions (atrophic gastric, pernicious anemia, *Helicobacter pylori* infections) or to the use of PPIs, is much more frequent than ZES, and cannot be excluded by assessing fasting gastrin levels alone or by a secretin provocative test, and thus require an assessment of gastric secretion by assessing gastric pH [31;62;64;66;68]. If the FSG is  $>10$  fold normal and the gastric pH  $<2$ , a diagnosis of ZES is established, (40%), however in the remaining 60 % of ZES the FSG is  $<10$  fold elevated with a gastric pH  $<2$  [29], additional testing is needed [1]. In patients taking PPIs where ZES is suspected, it should be remembered the diagnosis is not an emergency and should be undertaken only when the patient is stable and free of acid peptic disease and the PPI should not abruptly stopped [4;62–65]. Referral to a centre of excellence is preferred. If not possible an attempt to reduce the PPI dose/frequency, while monitoring the gastric pH as the PPIs are slowly withdrawn can be undertaken, with adequate coverage by high doses of H<sub>2</sub> blockers and careful patient monitoring [4;31;62;64].

**Minimum consensus statement on diagnosis in a patient with ZES, insulinoma (Figure 2) or RFT-specific MEN1**—Despite numerous guidelines [14], the diagnosis of MEN1 in patients with a F-pNET or in the presence of F-p-NETs is frequently associated with a markedly delayed (5–9.5 years) [12;73]. A recent study assessed risk factors of an ulterior diagnosis of MEN1 in patients with sporadic NETs [74]. In the 16% found to have MEN1, risk factors for MEN1 included: recurrent primary hyperparathyroidism [odds risk (OR) 162.4]; non-recurrent hyperparathyroidism (OR-26); presence of a p-NET - or duodenal NET (OR-18), pituitary tumor (OR-4.7), or positive family history of NET (OR-4.5) [74]. Recent studies confirm that in MEN1 patients, insulinomas occur earlier than gastrinomas and in 25% the insulinomas appear before the age of 20, which is rarely the case with gastrinomas [11;75–77]. Therefore if a patient is diagnosed with insulinoma before the age of 20 or with multiple insulinomas at any age, MEN1 should be suspected [4;75;77]. As outlined in the previous guidelines [1] it is essential all MEN1 patients be screened for p-NETs, both functional and non-functional and that this reassessment be repeated during follow-up.

### Minimum consensus statement on diagnosis of insulinoma

The exact criteria for the diagnosis of insulinoma continue to evolve and vary in different consensus documents and reviews [78–85]. In a consensus report from the US Endocrine Society [84] the following diagnostic criteria were proposed: endogenous hyperinsulinism documented by the finding of symptoms, signs, or both with plasma concentrations of glucose  $<55$  mg/dl (3.0 mmol/liter), insulin  $3.0$   $\mu$ U/ml (18 pmol/liter), C-peptide  $0.6$  ng/ml (0.2 nmol/liter), and proinsulin  $5.0$  pmol/liter. The presence of a

plasma  $\beta$ -hydroxybutyrate levels of  $>2.7$  mmol/liter and an increase in plasma glucose  $>25$  mg/dl (1.4 mmol/liter) after iv glucagon indicated mediation of the hypoglycemia by insulin (or by an IGF). The use of an insulin cut-off value of  $<3$  instead of  $<5$   $\mu$ U/mL is supported by a recent study showing that 9% of patients with insulinoma would be missed using the older recommended value of  $<5$  [81]. Another study [80] demonstrates that some patients with insulinoma (23%), can have plasma  $\beta$ -hydroxybutyrate levels of  $>2.7$  mmol/liter, especially if they have undergone previous partial pancreatectomy and are being evaluated for recurrence [80].

In contrast to other pNETs a recent study reports that evaluation of serum CgA levels are frequently not helpful for diagnosing patients with insulinoma, with an elevated CgA value having only a 73% specificity compared with 92% in non-insulinoma p-NET patients [86].

**Diagnosis of NF-p-NETs: laboratory tests**—Chromogranin A and PP were recommended as circulating tumor markers in NF- p-NETs in the previous guidelines. However, the percentage of patients with elevation of PP is lower than that of patients with elevation of chromogranin A [2].

Measurement of chromogranin A can be useful for diagnosis in a fraction of NF- p-NETs, and if elevated can be useful for evaluation of response to treatment, and to detect progression and recurrence at an early stage. Standardization of a chromogranin assay is needed [87].

In patients with NF-p-NETs developing hormonal symptoms, the appropriate plasma hormone/peptide concentration that could cause the symptomatology should be assessed and treatment may need to be changed [2].

## Localization of F-p-NETs and NF-p-NETs

### Localization of tumor/tumor extent in patients with F-p-NETs or NF-p-NETs

While somatostatin receptor scintigraphy with SPECT remains useful in staging pNETs, Numerous studies have demonstrated that imaging with positron emission tomography with CT (PET/CT) with  $^{68}\text{Ga}$  labeled somatostatin analogues has the highest sensitivity for localizing p-NETs, as well as generally for other NETs, and also has a high specificity. In various studies for p-NETs the sensitivity varies from 86–100%, and the specificity from 79–100% for all p-NETs [88–97], except insulinomas, in which case, its sensitivity is only 25% [98]. The result of these findings is that this method is now the method of choice to fully stage and localize the extent of disease in patients with noninsulinoma p-NETs [91;99]. Use of  $^{68}\text{Ga}$  labeled somatostatin analogues has been shown to change the management (surgical, medical, staging) in 20–55% of patients [95;96;100;101] and therefore it should generally be performed in patients with non-insulinoma p-NETs.

**ZES/other F-p-NETs and NF-p-NET localization**—In sporadic ZES gastrinomas occur in the duodenum in 60–80% and ZES/MEN1 patients, gastrinomas also occur primarily in the duodenum (90–100%), with 0–15% in the pancreas in different series [11;14;65;102–

104]. In sporadic ZES gastrinomas are known to occasionally occur in the liver (<1%) and liver/hepato-biliary system [65;105–107], and recently also in patients with MEN1/ZES [108]. Gastrinomas in these locations, especially the duodenum can be small (<0.5 cm) and multiple, therefore sensitive imaging, especially preoperatively is mandatory [65;109;110]. Recent studies show imaging with <sup>68</sup>Ga-labeled somatostatin analogs with PET/CT to be highly sensitive and specific for p-NETs, including gastrinoma [88;111;112] and NF-p-NETs to evaluate the location and stage the extent of disease[93;113]. Preoperative staging should include therefore at least SRS or preferably <sup>68</sup>Ga-DOTA-TOC/TATE/NOC-PET/CT [2]. Gallium-68 PET/CT, if available, should be considered as the first-line diagnostic imaging method for staging in patients with p-NETs [91]. Failing this, SRS/SPECT with EUS and OGD should be combined. In case of rapid tumor progression in earlier diagnosed G1-G2 tumors, <sup>18</sup>FDG-PET/CT may be considered to assess tumor burden and prognosis [114].

**MEN1 tumor localization. Minimum consensus statement on MEN-1**—A recent large prospective study [12] demonstrated that MEN-1 patients are living longer than in the past, however their life-expectancy is still shortened (mean age death, 55 years). In this study[12] as well as in the recent literature two thirds of MEN1 patients currently die from a MEN1-related cause and in 40–45% the principal cause is p-NET related. It thus remains essential to assess the presence and extent of any p-NET both attempting to identify a functional p-NET in a MEN-1 patient with symptoms, as well as asymptomatic non-functional p-NET (NF-p-NETs). A recent comparative study[115] demonstrates that both endoscopic ultrasound (EUS) and MRI give complementary results for identifying both tumors <2 cm or ≥ 2 cm, the cut-off assessed in this study because it is recommended in most guidelines for surgical exploration in MEN1 patients with NF-pNETs or gastrinomas [115]. However, in this study EUS missed 46% and MRI 17% of p-NETs ≥ 2 cm, and 16% and 19% of lesions >1cm [115], whereas in other studies, both EUS and MRI detected lesions this size[110;116–119]. This study recommends that they both be performed at the initial evaluation and that further study needs to be done to assess which to routinely perform on follow-up. At present this is unclear not only because it is not yet defined which will be the most sensitive for detecting clinically important changes, and also because at present, what rate of change should lead to surgery has not been defined.

Whereas imaging with <sup>68</sup>Ga labeled somatostatin analogues using PET/CT is the most sensitive modality for localizing p-NETs and other NETs, its routine use in MEN-1 patients is not yet defined. All would agree that it should be performed in any patient considered for surgery for a p-NET/NET as well as patients with advanced disease to fully stage the tumor extent, however it is not recommended as a screening study in an asymptomatic patient.

Patients with MEN-1 with insulinomas may need special localization methods, which are discussed, in the next section under insulinoma.

**Insulinoma-localization**—In a small percentage of patients with insulinomas (<5–10%) all conventional imaging studies including EUS are negative [85;98;110;120–122]. PET/CT scanning with <sup>68</sup>Ga labeled somatostatin analogues is only positive in 25–31% [88;98] of patients with insulinomas so that it will only be helpful in a minority of these patients. Two



other modalities continue to show promise in these patients and should be considered. Receptor scintigraphy with radiolabeled GLP-1 receptor analogues is a sensitive method, because insulinomas frequently overexpress this receptor [122–125], however, this is available in only a few centers. Functional localization after selective intra-arterial injection of calcium with hepatic venous insulin gradients (IACIG) has proved to be a highly sensitive method to localize insulinomas and is positive in 90–100% of cases [126;127] and therefore should be considered in a patient where other imaging tests are negative (see Algorithm, insulinoma)

Patients with MEN-1 and insulinoma present a special problem, because these patients often have multiple p-NETs imaged and most are NF-p-NETs, therefore singling out the insulinoma from NF-pNETs can be extremely difficult [14;109;128]. The use of IACIG can be particularly helpful in these patients and should be considered prior to surgery [14].

**RFT tumor localization. Minimum consensus statement on rare functional p-NETs**—In addition to CT scan and MRI and EUS (as outlined in the previous guidelines (1), recent studies show imaging with <sup>68</sup>Ga-labeled somatostatin analogs with PET/CT is more sensitive and highly specific for rare p-NETs also [88;92;93] and therefore it is recommended it be performed to evaluate and stage the extent of disease.

Gallium-68 PET/CT, if available, should be considered as the first-line diagnostic imaging method for staging in patients with rare p-NETs [91]. In case of rapid tumor growth in earlier diagnosed G1-G2 tumors, 18-FDG-PET/CT may be considered to assess tumor burden and prognosis [114].

## **Tumor Classification, Staging, Histopathology and Genetic sections of F-p-NETs and NF-p-NETs**

For p-NETs as well as other NETs, a number of TNM classification systems with grading have been developed (WHO2010 [World Health Organization], ENETs [European Neuroendocrine Tumor Society], AJCC [American Joint Committee on Cancer] [41;42;129]. The WHO 2010 classification [130] was described in the previous guidelines [2].

Each of these has been shown to have important prognostic value for p-NET patients and the routine use of one of these classification/grading systems is now essential to manage these patients [41–43;45;46;129;131–133]. Furthermore, proper classification and grading is now essential for selecting the correct treatment especially in patients with advanced or aggressive disease [134–137]. In many studies each of these classification/grading systems have prognostic value in p-NET patients [41;41–43;45;46;129;131;132;138]. However which should be preferred is at present not completely established. In one large comparative study of 1072 p-NETs patients the AJCC, WHO 2010 and ENETs TNM classification/grading systems were found to be independent predictors on multivariate analysis of survival, however the ENETs TNM classification was superior to the AJCC/WHO2010 classification/grading system and more accurate [138]. Recent reports from studies in p-NETs suggest that a Ki-67 proliferation index threshold of 5% could better distinguish G1 from G2 tumors, which should be further explored [2;130;138;139]. Because of the

important predictive value and effect on treatment approaches, if over time a patient demonstrates a more aggressive clinical course, a biopsy for reassessment of Ki-67 should be performed [140].

It has long been recognized that the development, presence and extent of liver metastases are one of the most important prognostic factors in patients with p-NETs, however the role of lymph node metastases as a prognostic factor has remained controversial. This is an important management point because it has a direct influence on the type of and extent of surgical procedure that should be performed. Recently, a number of studies have provided important information on this point: both demonstrating the presence of lymph node metastases can have important prognostic value as well as the extent of the lymph node metastases or lymph node positive ratio ([37;38;47–49;51;52;141].

There has been rapid progress from various molecular biological approaches into identifying factors important in the pathogenesis and/or prognosis of patients with p-NETs, especially from whole genome sequencing studies (i.e. identification of genes for MEN-1, DAXX/ATRAX, mTOR pathway, etc)[132;142–146]. However, at present none of these are routinely used in the clinical management of p-NET patients or in the classification systems. Therefore it is not recommended that any of these be routinely studied in p-NETs, except in the case of a possible occurrence of an inherited syndrome (MEN-1, VHL, etc.).

Recently it has become clear that 5–10% of patients who clinically fit the criteria for MEN-1, do not have mutations in the MEN-1 gene, however some of these patients (1.5%) have mutations in the cyclin-dependent kinase inhibitor gene, CDK1B, which encodes for p27kip1 (p27), a cyclin-dependent kinase inhibitor that regulates the transition of cells from G1 to S phase, and are now classified as MEN-4. Others have germline mutations of the cyclin-dependent kinase inhibitors p15, p18 and p21, which are a probable cause of MEN1 in approximately 1, 0.5 and 0.5% of patients [14;147;148].

**Pathology/Genetics of all p-NETs**—In all patients, p-NETs should be classified and graded using the current WHO 2010 classification and grading system. One recent study [149] shows a good correlation in grading between tissue samples and fine-needle aspirations at EUS, however, use of EUS samples for grading needs further confirmation.

In patients with non-insulinoma p-NETs at the time of surgery a routine dissection and harvesting of possible involved lymph nodes should be performed.

In the 5–10% of patients with an MEN1 phenotype but no mutations in the MEN1 gene are found, consideration should be given to performing genetic studies for mutations in cyclic-dependent kinase inhibitor genes (CDK1B, p15, p18, p21).

For metastatic NETs with unknown primary, the expression of Is11 and PAX8 could indicate pancreatic origin [150;151].

## Surgery for F-p-NETs and NF-p-NETs (see algorithm)

**Surgical treatment of ZES-General**—There have been a number of surgical studies effecting the approach to ZES patients [38;51;102;141;152–155]. The role of surgery in ZES patients without MEN1 with negative pre-operative imaging has been controversial. A recent study [152] provides evidence that all sporadic ZES patients will benefit from surgical exploration for cure, just as much as patients with pre-surgically identified tumours. In this study [152] the disease-free rate postresection was higher in the patients with negative imaging than with positive imaging and the 20 year disease free survival was higher, with tumors found in >98% of patient with or without imaged tumors. Therefore the recommendation is that all patients without MEN1 with ZES who do not have a medical contraindication should have surgical exploration by a surgeon well-versed in the treatment of gastrinoma.

The presence of lymph node metastases as a prognostic factor has been unclear with different studies giving different results. Recent studies [37;38;48;49;51;52;141] now report in patients with p-NETs that lymph node status and number of nodes in some studies has important prognostic value. In addition to the prognostic value of the presence of lymph node metastases, in gastrinoma studies show their resection can reduce the occurrence of persistent disease and improve survival [102;135;141] perhaps in some cases by resecting lymph node primary gastrinomas. This result supports the recommendation that systematic removal of lymph nodes in the peritumoral area should be part of any gastrinoma operation.

Resection of pancreatic tumors with possible major vascular involvement is controversial both in the case of p-NETs and other pancreatic neoplasms. A recent study [156] demonstrated in a group of p-NETs patients (65%-ZES) with CT evidence of major vascular involvement, that in 91% the p-NET could be safely removed, vascular reconstruction was required in 19%; postoperatively 30% were disease free and 10-year survival was 62%. This result, combined with other recent reports [157–160], support the conclusion that surgical resection should be considered in patients with p-NETs with preoperative vascular abutment or invasion by a group well versed in this type of surgery.

The surgical treatment of patients with MEN1/ZES, as with patients with MEN1 with nonfunctional p-NETs, continues to remain controversial [14;31;103;104;109;155;161;161;162]. Additional studies demonstrate that patients with MEN1/ZES, despite generally having multiple small duodenal gastrinomas, frequently with positive lymph node metastases, can be cured by extensive surgery such as a pancreaticoduodenectomy. However, at present, this operation remains not routinely recommended [1;11;163] because of its potential short/long-term complications, the fact that patients with p-NETs > 2 cm have an excellent long term prognosis with survival rates of up to 100% at 15 years of follow-up [1;11;31;161] and in the MEN1/ZES patients, gastric hypersecretion can be well controlled medically [4;54].

### **Additional Minimum consensus statement on surgical treatment of gastrinomas**

All patients with sporadic gastrinomas who do not have a medical contraindication should have surgical exploration by a surgeon well versed in the treatment of gastrinoma [152].

As part of any gastrinoma operation systematic removal of lymph nodes in the peritumoral area that can be assessed for its prognostic value as well as possibility of increasing the cure rate.

A group well versed in this type of surgery should consider surgical resection in patients with p-NETs with preoperative vascular abutment or invasion.

In patients with MEN1/ZES with ZES with p-NETs  $\leq 2$  cm or with NF-pNETs on imaging studies, routine surgical exploration continues not to be generally recommended. In patients with p-NETs  $>2$  cm, enucleation at surgery remains the generally recommended surgical procedure, with pancreaticoduodenotomy reserved for specific, selected cases [1;31;103; 109; 161;163].

**Surgical treatment of insulinoma-General**—A number of studies continue to demonstrate that in both adults and in children, surgical exploration results in a high cure rate (98–100%)[39;164–167]. In most cases enucleation of the insulinoma is possible with a more extensive resection required in the remainder [39;164–167]. A recent systematic review [168] provides support for a laparoscopic approach which is not only safe but is associated with reduced hospitalization stay, but also achieves comparable cure rates to open surgery. In MEN1 patients with insulinomas (25%) surgery should also be performed whenever metastatic disease is not present (90–97%), and enucleation or limited resection remain the procedure of choice [109;128]. A laparoscopic approach has been successful in selected group of MEN1 patients with imaged insulinomas [169–171].

Use of ablative therapy either endoscopically directed or percutaneously with radiological direction has also been reported to be successful. Reports of EUS directed ablation using ethanol injection or CT-guided RFA have all been successful with either insulinomas in patients with sporadic disease or with MEN1 [39;164–167].

### **Additional Minimum consensus statement on surgical treatment of insulinomas**

Surgical exploration for possible cure should be performed in all patients with insulinomas if non-resectable metastatic disease is not present with or without MEN1. A laparoscopic approach is generally recommended in patients with sporadic disease with imaged tumors [171].

In the uncommon patient who is not thought to be a surgical candidate with a localized insulinoma, the use of ablative therapy either endoscopically directed or percutaneously with radiological direction have been reported but further data is required can be

successful. Reports of EUS directed ablation using ethanol injection or CT-guided RFA have all been successful. [39;164–167].

### **Additional Minimum consensus statement on surgical treatment of NF-p-NETS**

Attempted curative resection continues to be recommended whenever nonresectable metastatic disease is not present in all patients with rare or very rare functional p-NETs [1;2;163;167]. A laparoscopic approach can be used in localized imaged RF p-NETs [1;171–173]. In patients with MEN1 with NF-p-NETs  $\leq 2$  cm or with on imaging studies, routine surgical exploration continues not to be generally recommended. In patients with p-NETs  $>2$  cm, enucleation/local resection at surgery remains possible in many patients, with pancreaticoduodenotomy reserved for specific, selected cases [1; 2;163; 167].

**Surgical treatment of NF-P-NETs versus observation**—Several studies explored the safety and feasibility of a non-operative management approach for asymptomatic sporadic NF-p-NET  $\leq 2$  cm above all when a major pancreatic resection is required. A conservative approach seems to be safe as the majority of the observed tumors did not show any significant changes during follow-up [39; 174;175]. However follow-up data are needed to guarantee the safety of this policy. The long-term outcome of resected VHL-p-NETs is better than that of sporadic NF-p-NETs and lesions  $\leq 15$  mm in size can be safely managed with non-operative treatment [176]. Moreover a recent paper reported that in VHL NF-p-NETs demonstrate a non-linear growth pattern, which includes periods of no growth and apparent decrease in size by imaging. Tumor density may offer a specific diagnostic tool for malignant disease [177].

Recent data suggested the value of an extended surgical resection for advanced p-NETs [157;177]. In this context simultaneous surgical resection of liver metastases and primary tumor could be performed with low mortality and morbidity as suggested in a recent small study [177]. However a simultaneous pancreaticoduodenectomy and a major hepatectomy must be avoided due to the high morbidity and mortality rate [177].

## **Medical therapy of F-p-NETs (see algorithm)**

**Medical treatment of ZES-General**—A number of publications have reviewed various aspects of medical therapy of the gastric acid hypersecretion and other features of ZES since the 2011 guidelines [4;54;63]. Proton pump inhibitors remain the drugs of choice to control acid hypersecretion in all patients who can take oral medication with once or twice a day dosing. PPI appear to remain one of the safest drugs with long-term use with minimal side effects. Recent studies demonstrate that hypomagnesemia can develop in patients taking PPIs and it is a PPI drug class effect [178–181]. A number of epidemiologic studies have reported an increased incidence of bone fractures in patients on long term PPI treatment without ZES although this finding is disputed in other studies. Monitoring for the development of vitamin B12 deficiency with long-term PPI treatment in ZES patients

continues to be advised especially in the elderly or in patients with previous malabsorption [178;182–184].

The effect of curative resection on acid hypersecretion in ZES patients has not been systematically studied until recently and its management is controversial. A study of 50 such ZES patients [185] demonstrated that despite being cured, 62% remained hypersecretors and in 28% acid output remained very high (BAO's>2.5 normal), and it lasted for up to 8 years. These patients were found to have increased ECL postoperative changes and activity, but the mechanism was not clearly defined. This study [185] concluded that a high proportion ZES patients undergoing a surgical “cure” continue to require gastric acid suppressive treatment and thus they should be carefully monitored and the PPIs not abruptly stopped postoperatively.

#### **Minimum consensus statement on medical treatment of ZES**

Acid hypersecretion in ZES should be controlled at all times with the drugs of choice being PPIs (once or twice daily) [4;54;65]. Surveillance involves assessing continued acid control, monitoring for vitamin B12 deficiency and being aware hypomagnesemia is more frequent in patients taking PPIs and it is a PPI drug class effect. Patients who are cured surgically may continue to be gastric acid hypersecretors and require frequent monitoring and most (60%) required continue antisecretory drugs, although usually at lower doses.

**Medical treatment of insulinomas-General**—Prior to surgery or in the small percentage with malignant disease (<10%), besides treating the hypoglycemia with small frequent meals and diazoxide, approximately 30–50% will respond to somatostatin analogues, although they need to be carefully monitored because a proportion may get worse on this treatment [4;135;186–190]. Numerous recent reports demonstrate that the mTOR inhibitor everolimus is effective in these patients with malignant insulinomas at controlling the hypoglycemia [4;135;187–189;191] and in one case sunitinib was also shown to be effective [192]. Antitumor treatment with PRRT or bland or chemoembolization can also control the hypoglycemia in patients with malignant insulinomas [135;193–195].

#### **Minimum consensus statement on medical treatment of insulinomas**

Surgery remains the preferred treatment whenever possible, but prior to surgery, recurrent cases and in malignant insulinomas medical treatment is needed. In addition to diazoxide, frequent small meals, somatostatin analogs, and the mTOR inhibitor everolimus has been effective in controlling hypoglycemia in an increasing number of reports. Sunitinib also was effective in a few patients and in malignant insulinomas, PRRT or chemoembolization can help control the hypoglycemia.

**Medical treatment of RF-p-NETs-General**—Somatostatin analogues remain the treatment of choice for functional RF-p-NETs for the hormone excess state prior to surgery

or if resection can not be performed, with recent reports of their effectiveness in PTHrPomas, ACTHomas, VIPomas GRFomas and other RF-p-NETs [5;27;190;196–198].

## Treatment of advanced, metastatic p-NETs (to be covered in special chapter on metastatic NETs)

### Loco-regional ablative therapy

**Selective embolization**—HAE and HACE are contraindicated in patients who have undergone Whipple's procedure [3;135].

**MEDICAL TREATMENT**—See revision of ENETS 2011 guidelines for management distant metastases of intestinal, pancreatic, bronchial NET and NET of unknown origin [3]

### PRRT (peptide receptor-targeted radiotherapy)

Promising data have evolved with regard to PRRT in the treatment of NETs including p-NETs with distant metastases using <sup>90</sup>Yttrium-DOTATOC or <sup>177</sup>Lutetium-DOTATATE [157;199–201]. PRRT can be considered in both F-p-nets and NF-p-NETs with high and homogenous expression of somatostatin receptors irrespective of the site of the primary tumor. Based on phase II trials, more than 1,000 patients have been treated in Europe with complete or partial objective responses in up to 30–40 % and a progression-free survival of 17–40 months [157;199–201]. Results from prospective randomized trials comparing PRRT with other therapeutic options are lacking, but a phase III trial comparing PRRT with octreotide is ongoing (NETTER-1, NCT01578239). PRRT is still considered investigational and its implementation must comply to national legislation and ethical guidelines [202].

For PRRT treatment the following requirements should be fulfilled: 1) NET proven by histopathology; 2) high somatostatin receptor expression (sstr2) determined by functional imaging with SRS or <sup>69</sup>Ga-DOTA-peptide PET/CT; 3) Karnofsky index should be >60% or ECOG <2; 4) WHO grade 1/2, and Ki-67 <20% [202].

Dose-limiting organs are the kidneys and the bone marrow. For PRRT with <sup>90</sup>Y-labeled peptide, which is considered more nephrotoxic, normal renal function is required. For <sup>177</sup>Lu-labeled peptide a mild renal impairment can be tolerated, but a glomerular filtration rate (GFR) should be at least 60% of mean age-adjusted normal values. Liver function parameters required: total bilirubin <3 ULN, albumin >30 g/l and PK normal. Bone marrow function should fulfill the following reference values: WBC > 3 × 10<sup>9</sup>; PLT >75 × 10<sup>9</sup> for <sup>177</sup>Lu-DOTATATE, 90 × 10<sup>9</sup> for <sup>90</sup>Y-DOTATOC; Hg >5 mmol/l (8 g/dl); The minimum requirements for PRRT are described in separate consensus guidelines [202;203].

There are different research protocols in use, and there is no standard with regard to number of cycles or activity of cycles with PRRT. The interval between courses should be at least 6 weeks and may be longer if toxicity occurs. Individualized treatment guided by dosimetry of kidney and bone is being explored [204].

The treatment is generally well tolerated, but serious side-effects may occur, including severe bone marrow disease (acute myelogenous leukemia, myelodysplastic syndrome) both

in patients with and without previous chemotherapy. Kidney failure has been seen, especially with  $^{90}\text{Y}$ -treatment but protective amino acid infusion are routinely given to avoid this complication. Patients with pending liver failure are not candidates for PRRT.

PRRT is still not considered as first-line treatment but can be recommended in advanced NET after failure of medical treatment and should be used within clinical study protocols.

## Follow-up during treatment with F-p-NETs and NF-p-NETs

Follow-up during treatment should include measurement of biochemical markers and conventional imaging (CT and/or MR) every 3 to 9 months in patients with G1 and G2 tumors. The interval between assessment can be increased if disease is stable (this is especially for indolent G1 tumours). Somatostatin receptor imaging if positive should be repeated every 2 years or earlier if progression is suspected.

Please also refer to consensus guideline updates for other gastro-entero-pancreatic (GEP) neuroendocrine tumours [205–210, this issue].

## ANNEX 1

### Rare and very rare functional pancreatic neuroendocrine tumours

Even though all the rare functional p-NETs (RFTs) are considered as a group, as recently pointed out [4] they actual comprise two different groups: the rare F-p-NETs (VIPoma, glucagonoma, GRFoma, ACTHomas, RFTs causing carcinoid syndrome or hypercalcemia (PTHrPomas) and, somatostatinomas, in which there are more than 100 cases described [5], and a second group: the very rare F-p-NETs (p-NETs secreting renin, luteinizing hormone, erythropoietin, Glucagon-like peptide-1 (GLP-1), Insulin-like growth factor-2 (IGF-II), and cholecystokinin (CCK) (CCKoma))[1] for which 1–5 cases have been described [4;6;7]) (see revised Table 1). The only new functional syndromes described since the 2011 guidelines are the ectopic secretion of GLP-1 [6] and CCK (CCKoma) [7] from a p-NET. The GLP-1 secreting p-NET caused both diabetes and hypoglycemic symptoms, similar to previously reported in a patient with an ovarian stromal NET secreting GLP-1 [8]. Patients with functional CCKomas had not been previously described, however, recently a single well-described case was documented [7] in a patient who had diarrhea, cholelithiasis, severe weight loss and a bleeding peptic ulcer with normal fasting serum gastrin levels, but plasma CCK levels were increased >100-fold. Thus this patient mimics many of the features of a patient with ZES with normal fasting gastrin levels [7].

Not listed in Table 1 as F-p-NET syndromes are p-NETs secreting calcitonin, neurotensin, pancreatic polypeptide (PP) and ghrelin, all of which have been proposed to be functional syndromes in some papers [4;9;10]. However, in numerous series there are frequent asymptomatic patients with p-NETs described with elevated levels of these hormones and at present most authorities continue not to accept these as distinct F-p-NETs syndromes [4;9].

Recently a new syndrome [15] was described involving the development of duodenal somatostatinomas, paragangliomas and the presence of polycythemia, with gain of function HIF2A mutations in the tumors, but not the germline. A possible new genetic disorder,



Mahvash disease, has been reported which is caused by inactivating mutations of the human glucagon receptor and is associated with the development of  $\alpha$ -cell hyperplasia, hyperglucagonemia and the development of NF-p-NETs[16]. This disorder is reproduced in glucagon receptor deficient mice [16;17]. At present it is unknown if this disease is inherited and expressed in different generations.

## References

1. Jensen RT, Cadiot G, Brandi ML, et al. ENETS Consensus Guidelines for the Management of Patients with Digestive Neuroendocrine Neoplasms: Functional Pancreatic Endocrine Tumor Syndromes. *Neuroendocrinology*. 2012; 95:98–119. [PubMed: 22261919]
2. Falconi M, Bartsch DK, Eriksson B, et al. ENETS Consensus Guidelines for the Management of Patients with Digestive Neuroendocrine Neoplasms of the Digestive System: Well-Differentiated Pancreatic NonFunctioning Tumors. *Neuroendocrinology*. 2012; 95:120–134. [PubMed: 22261872]
3. Pavel M, Baudin E, Couvelard A, et al. ENETS Consensus Guidelines for the Management of Patients with Liver and Other Distant Metastases from Neuroendocrine Neoplasms of Foregut, Midgut, Hindgut, and Unknown Primary. *Neuroendocrinology*. 2012; 95:157–176. [PubMed: 22262022]
4. Ito T, Igarashi H, Jensen RT. Pancreatic neuroendocrine tumors: clinical features, diagnosis and medical treatment: *Advances. Best Pract Res Clin Gastroenterol*. 2012; 26:737–753. [PubMed: 23582916]
5. Garby L, Caron P, Claustrat F, et al. Clinical characteristics and outcome of acromegaly induced by ectopic secretion of growth hormone-releasing hormone (GHRH): a French nationwide series of 21 cases. *J Clin Endocrinol Metab*. 2012; 97:2093–2104. [PubMed: 22442262]
6. Roberts RE, Zhao M, Whitelaw BC, et al. GLP-1 and Glucagon Secretion from a Pancreatic Neuroendocrine Tumor Causing Diabetes and Hyperinsulinemic Hypoglycemia. *J Clin Endocrinol Metab*. 2012; 97:3039–3045. [PubMed: 22774207]
7. Rehfeld JF, Federspiel B, Bardram L. A neuroendocrine tumor syndrome from cholecystokinin secretion. *N Engl J Med*. 2013; 368:1165–1166. [PubMed: 23514309]
8. Todd JF, Stanley SA, Roufosse CA, et al. A tumour that secretes glucagon-like peptide-1 and somatostatin in a patient with reactive hypoglycaemia and diabetes. *Lancet*. 2003; 361:228–230. [PubMed: 12547550]
9. Schneider R, Waldmann J, Swaid Z, et al. Calcitonin-secreting pancreatic endocrine tumors: systematic analysis of a rare tumor entity. *Pancreas*. 2011; 40:213–221. [PubMed: 21178652]
10. Wang HS, Oh DS, Ohning GV, et al. Elevated serum ghrelin exerts an orexigenic effect that may maintain body mass index in patients with metastatic neuroendocrine tumors. *J Mol Neurosci*. 2007; 33:225–231. [PubMed: 17952631]
11. Jensen RT, Berna MJ, Bingham MD, et al. Inherited pancreatic endocrine tumor syndromes: advances in molecular pathogenesis, diagnosis, management and controversies. *Cancer*. 2008; 113(7 suppl):1807–1843. [PubMed: 18798544]
12. Ito T, Igarashi H, Uehara H, et al. Causes of Death and Prognostic Factors in Multiple Endocrine Neoplasia Type 1: A Prospective Study: Comparison of 106 MEN1/Zollinger-Ellison Syndrome Patients With 1613 Literature MEN1 Patients With or Without Pancreatic Endocrine Tumors. *Medicine (Baltimore)*. 2013; 92:135–181. [PubMed: 23645327]
13. Levy-Bohbot N, Merle C, Goudet P, et al. Prevalence, characteristics and prognosis of MEN 1-associated glucagonomas, VIPomas, and somatostatinomas: study from the GTE (Groupe des Tumeurs Endocrines) registry. *Gastroenterol Clin Biol*. 2004; 28:1075–1081. [PubMed: 15657529]
14. Thakker RV, Newey PJ, Walls GV, et al. Clinical Practice Guidelines for Multiple Endocrine Neoplasia Type 1 (MEN1). *J Clin Endocrinol Metab*. 2012; 97:2990–3011. [PubMed: 22723327]
15. Pacak K, Jochmanova I, Prodanov T, et al. New syndrome of paraganglioma and somatostatinoma associated with polycythemia. *J Clin Oncol*. 2013; 31:1690–1698. [PubMed: 23509317]
16. Yu R. Pancreatic alpha-cell hyperplasia: facts and myths. *J Clin Endocrinol Metab*. 2014; 99:748–756. [PubMed: 24285676]

17. Yu R, Wawrowsky K, Zhou C. A natural inactivating mutant of human glucagon receptor exhibits multiple abnormalities in processing and signaling. *Endocrinol Nutr.* 2011; 58:258–266. [PubMed: 21680267]
18. Yao JC, Hassan M, Phan A, et al. One hundred years after “carcinoid”: epidemiology of and prognostic factors for neuroendocrine tumors in 35,825 cases in the United States. *J Clin Oncol.* 2008; 26:3063–3072. [PubMed: 18565894]
19. Capelli P, Fassan M, Scarpa A. Pathology - Grading and staging of GEP-NETs. *Best Pract Res Clin Gastroenterol.* 2012; 26:705–717. [PubMed: 23582914]
20. Ito T, Igarashi H, Nakamura K, et al. Epidemiological trends of pancreatic and gastrointestinal neuroendocrine tumors in Japan: a nationwide survey analysis. *J Gastroenterol.* 2014
21. Cho MY, Kim JM, Sohn JH, et al. Current Trends of the Incidence and Pathological Diagnosis of Gastroenteropancreatic Neuroendocrine Tumors (GEP-NETs) in Korea 2000–2009: Multicenter Study. *Cancer Res Treat.* 2012; 44:157–165. [PubMed: 23091441]
22. Tsai HJ, Wu CC, Tsai CR, et al. The epidemiology of neuroendocrine tumors in Taiwan: a nationwide cancer registry-based study. *PLoS ONE.* 2013; 8:e62487. [PubMed: 23614051]
23. Scherubl H, Steller B, Stabenow R, et al. Clinically detected gastroenteropancreatic neuroendocrine tumors are on the rise: epidemiological changes in Germany. *World J Gastroenterol.* 2013; 19:9012–9019. [PubMed: 24379626]
24. Halfdanarson TR, Rabe KG, Rubin J, et al. Pancreatic neuroendocrine tumors (PNETs): incidence, prognosis and recent trend toward improved survival. *Ann Oncol.* 2008; 10:1727–1733. [PubMed: 18515795]
25. Sharma J, Duque M, Saif MW. Emerging therapies and latest development in the treatment of unresectable pancreatic neuroendocrine tumors: an update for clinicians. *Therap Adv Gastroenterol.* 2013; 6:474–490.
26. Lee LC, Grant CS, Salomao DR, et al. Small, nonfunctioning, asymptomatic pancreatic neuroendocrine tumors (PNETs): role for nonoperative management. *Surgery.* 2012; 152:965–974. [PubMed: 23102679]
27. Kamp K, Feelders RA, van Adrichem RC, et al. Parathyroid Hormone-Related Peptide (PTHrP) Secretion by Gastroenteropancreatic Neuroendocrine Tumors (GEP-NETs): Clinical Features, Diagnosis, Management, and Follow-Up. *J Clin Endocrinol Metab.* 2014; 99:3060–3069. [PubMed: 24905065]
28. Garbrecht N, Anlauf M, Schmitt A, et al. Somatostatin-producing neuroendocrine tumors of the duodenum and pancreas: incidence, types, biological behavior, association with inherited syndromes, and functional activity. *Endocr Relat Cancer.* 2008; 15:229–241. [PubMed: 18310290]
29. Berna MJ, Hoffmann KM, Serrano J, et al. Serum gastrin in Zollinger-Ellison syndrome: I. Prospective study of fasting serum gastrin in 309 patients from the National Institutes of Health and comparison with 2229 cases from the literature. *Medicine (Baltimore).* 2006; 85:295–330. [PubMed: 17108778]
30. Berna MJ, Hoffmann KM, Long SH, et al. Serum gastrin in Zollinger-Ellison syndrome: II. Prospective study of gastrin provocative testing in 293 patients from the National Institutes of Health and comparison with 537 cases from the literature. evaluation of diagnostic criteria, proposal of new criteria, and correlations with clinical and tumoral features. *Medicine (Baltimore).* 2006; 85:331–364. [PubMed: 17108779]
31. Ito T, Igarashi H, Jensen RT. Zollinger-Ellison syndrome: Recent advances and controversies. *Current Opinion in Gastroenterology.* Oct 1.2013 29:650–661. [PubMed: 24100728]
32. Rehfeld JF, Bardram L, Hilsted L, et al. Pitfalls in diagnostic gastrin measurements. *Clin Chem.* 2012; 58:831–836. [PubMed: 22419747]
33. Rehfeld JF, Gingras MH, Bardram L, et al. The Zollinger-Ellison Syndrome and Mismeasurement of Gastrin. *Gastroenterology.* 2011; 140:1444–1453. [PubMed: 21315717]
34. Poultides GA, Huang LC, Chen Y, et al. Pancreatic neuroendocrine tumors: radiographic calcifications correlate with grade and metastasis. *Ann Surg Oncol.* 2012; 19:2295–2303. [PubMed: 22396008]

35. Panzuto F, Merola E, Rinzivillo M, et al. Advanced digestive neuroendocrine tumors: metastatic pattern is an independent factor affecting clinical outcome. *Pancreas*. 2014; 43:212–218. [PubMed: 24518498]
36. Panzuto F, Boninsegna L, Fazio N, et al. Metastatic and Locally Advanced Pancreatic Endocrine Carcinomas: Analysis of Factors Associated With Disease Progression. *J Clin Oncol*. 2011; 29:2372–2377. [PubMed: 21555696]
37. Boninsegna L, Panzuto F, Partelli S, et al. Malignant pancreatic neuroendocrine tumour: Lymph node ratio and Ki67 are predictors of recurrence after curative resections. *Eur J Cancer*. 2012; 48:1608–1615. [PubMed: 22129889]
38. Hashim YM, Trinkaus KM, Linehan DC, et al. Regional lymphadenectomy is indicated in the surgical treatment of pancreatic neuroendocrine tumors (PNETs). *Ann Surg*. 2014; 259:197–203. [PubMed: 24253141]
39. Crippa S, Partelli S, Zamboni G, et al. Incidental diagnosis as prognostic factor in different tumor stages of nonfunctioning pancreatic endocrine tumors. *Surgery*. 2014; 155:145–153. [PubMed: 24646958]
40. Birnbaum DJ, Gaujoux S, Cherif R, et al. Sporadic nonfunctioning pancreatic neuroendocrine tumors: prognostic significance of incidental diagnosis. *Surgery*. 2014; 155:13–21. [PubMed: 24238123]
41. Rindi G, Petrone G, Inzani F. The 2010 WHO classification of digestive neuroendocrine neoplasms: a critical appraisal four years after its introduction. *Endocr Pathol*. 2014; 25:186–192. [PubMed: 24699927]
42. Klimstra DS. Pathology reporting of neuroendocrine tumors: essential elements for accurate diagnosis, classification, and staging. *Semin Oncol*. 2013; 40:23–36. [PubMed: 23391110]
43. Yang M, Tian BL, Zhang Y, et al. Evaluation of the world health organization 2010 grading system in surgical outcome and prognosis of pancreatic neuroendocrine tumors. *Pancreas*. 2014; 43:1003–1008. [PubMed: 24945681]
44. Wong J, Fulp WJ, Strosberg JR, et al. Predictors of lymph node metastases and impact on survival in resected pancreatic neuroendocrine tumors: a single-center experience. *Am J Surg*. 2014
45. Morin E, Cheng S, Mete O, et al. Hormone profiling, WHO 2010 grading, and AJCC/UICC staging in pancreatic neuroendocrine tumor behavior. *Cancer Med*. 2013; 2:701–711. [PubMed: 24403235]
46. Liu TC, Hamilton N, Hawkins W, et al. Comparison of WHO Classifications (2004, 2010), the Hochwald grading system, and AJCC and ENETS staging systems in predicting prognosis in locoregional well-differentiated pancreatic neuroendocrine tumors. *Am J Surg Pathol*. 2013; 37:853–859. [PubMed: 23598967]
47. Partelli S, Gaujoux S, Boninsegna L, et al. Pattern and clinical predictors of lymph node involvement in nonfunctioning pancreatic neuroendocrine tumors (NF-PanNETs). *JAMA Surg*. 2013; 148:932–939. [PubMed: 23986355]
48. Han X, Xu X, Jin D, et al. Clinicopathological characteristics and prognosis-related factors of resectable pancreatic neuroendocrine tumors: a retrospective study of 104 cases in a single chinese center. *Pancreas*. 2014; 43:526–531. [PubMed: 24658317]
49. Ricci C, Casadei R, Taffurelli G, et al. The role of lymph node ratio in recurrence after curative surgery for pancreatic endocrine tumours. *Pancreatol*. 2013; 13:589–593. [PubMed: 24280574]
50. Casadei R, Ricci C, Tomassetti P, et al. Factors related to long-term survival in patients affected by well-differentiated endocrine tumors of the pancreas. *ISRN Surg*. 2012; 2012:1–5.
51. Parekh JR, Wang SC, Bergsland EK, et al. Lymph Node Sampling Rates and Predictors of Nodal Metastasis in Pancreatic Neuroendocrine Tumor Resections: The UCSF Experience With 149 Patients. *Pancreas*. 2012; 41:840–844. [PubMed: 22781907]
52. Tsutsumi K, Ohtsuka T, Mori Y, et al. Analysis of lymph node metastasis in pancreatic neuroendocrine tumors (PNETs) based on the tumor size and hormonal production. *J Gastroenterol*. 2012; 47:678–685. [PubMed: 22350698]
53. Marinoni I, Kurrer AS, Vassella E, et al. Loss of DAXX and ATRX are associated with chromosome instability and reduced survival of patients with pancreatic neuroendocrine tumors. *Gastroenterology*. 2014; 146:453–460. [PubMed: 24148618]

54. Ito T, Igarashi H, Uehara H, et al. Pharmacotherapy of Zollinger-Ellison syndrome. *Expert Opin Pharmacotherapy*. 2013; 14:307–321.
55. Goudet P, Murat A, Binquet C, et al. Risk factors and causes of death in MEN1 disease. A GTE (Groupe d'Etude des Tumeurs Endocrines) cohort study among 758 patients. *World J Surg*. 2010; 34:249–255. [PubMed: 19949948]
56. Gibril F, Chen Y-J, Schrupp DS, et al. Prospective study of thymic carcinoids in patients with Multiple Endocrine Neoplasia Type 1. *J Clin Endocrinol Metab*. 2003; 88:1066–1081. [PubMed: 12629087]
57. Goudet P, Murat A, Cardot-Bauters C, et al. Thymic neuroendocrine tumors in multiple endocrine neoplasia type 1: a comparative study on 21 cases among a series of 761 MEN1 from the GTE (Groupe des Tumeurs Endocrines). *World J Surg*. 2009; 33:1197–1207. [PubMed: 19294466]
58. Wilson SD, Doffek KM, Krzywda EA, et al. Zollinger-Ellison syndrome associated with a history of alcohol abuse: Coincidence or consequence? *Surgery*. 2011; 150:1129–1135. [PubMed: 22136832]
59. Toaiari M, Davi MV, Dalle Carbonare L, et al. Presentation, diagnostic features and glucose handling in a monocentric series of insulinomas. *J Endocrinol Invest*. 2013; 36:753–758. [PubMed: 23608735]
60. Iida K, Ohara T, Hino Y, et al. Glucose-responsive insulinoma in a patient with postprandial hypoglycemia in the morning. *Intern Med*. 2010; 49:2123–2127. [PubMed: 20930440]
61. Del Sindaco P, Casucci G, Pampanelli S, et al. Late post-prandial hypoglycaemia as the sole presenting feature of secreting pancreatic beta-cell adenoma in a subtotally gastrectomized patient. *Eur J Endocrinol*. 1997; 136:96–99. [PubMed: 9037134]
62. Ito T, Cadiot G, Jensen RT. Diagnosis of Zollinger-Ellison syndrome: Increasingly difficult. *World J Gastroenterol*. 2012; 18:5495–5503. [PubMed: 23112541]
63. Poitras P, Gingras MH, Rehfeld JF. The Zollinger-Ellison syndrome: dangers and consequences of interrupting antisecretory treatment. *Clin Gastroenterol Hepatol*. 2012; 10:199–202. [PubMed: 21871248]
64. Metz DC. Diagnosis of the Zollinger-Ellison syndrome. *Clin Gastroenterol Hepatol*. 2012; 10:126–130. [PubMed: 21806955]
65. Jensen RT, Niederle B, Mitry E, et al. Gastrinoma (duodenal and pancreatic). *Neuroendocrinology*. 2006; 84:173–182. [PubMed: 17312377]
66. Poitras P, Gingras MH, Rehfeld JF. Secretin stimulation test for gastrin release in Zollinger-Ellison syndrome: to do or not to do? *Pancreas*. 2013; 42:903–904. [PubMed: 23851427]
67. Shibata C, Kakyo M, Kinouchi M, et al. Criteria for the glucagon provocative test in the diagnosis of gastrinoma. *Surg Today*. 2013; 43:1281–1285. [PubMed: 22983734]
68. Shah P, Singh MH, Yang YX, et al. Hypochlorhydria and achlorhydria are associated with false-positive secretin stimulation testing for Zollinger-Ellison syndrome. *Pancreas*. 2013; 42:932–936. [PubMed: 23851430]
69. Ito T, Igarashi H, Jensen RT. Serum pancreastatin: the long sought universal, sensitive, specific tumor marker for neuroendocrine tumors? *Pancreas*. 2012; 41:505–507. [PubMed: 22504376]
70. Kanakis G, Kaltsas G. Biochemical markers for gastroenteropancreatic neuroendocrine tumours (GEP-NETs). *Best Pract Res Clin Gastroenterol*. 2012; 26:791–802. [PubMed: 23582919]
71. Rehfeld JF, Bardram L, Hilsted L, et al. An evaluation of chromogranin A versus gastrin and progastrin in gastrinoma diagnosis and control. *Biomark Med*. 2014; 8:571–580. [PubMed: 24796622]
72. Roy PK, Venzon DJ, Feigenbaum KM, et al. Gastric secretion in Zollinger-Ellison syndrome: correlation with clinical expression, tumor extent and role in diagnosis - A prospective NIH study of 235 patients and review of the literature in 984 cases. *Medicine(Baltimore)*. 2001; 80:189–222. [PubMed: 11388095]
73. Yamazaki M, Suzuki S, Kosugi S, et al. Delay in the diagnosis of multiple endocrine neoplasia type 1: typical symptoms are frequently overlooked. *Endocr J*. 2012; 59:797–807. [PubMed: 22673601]
74. de Laat JM, Tham E, Pieterman CR, et al. Predicting the risk of multiple endocrine neoplasia type 1 for patients with commonly occurring endocrine tumors. *Eur J Endocrinol*. 2012; 167:181–187. [PubMed: 22581216]

75. Sakurai A, Yamazaki M, Suzuki S, et al. Clinical features of insulinoma in patients with multiple endocrine neoplasia type 1: analysis of the database of the MEN Consortium of Japan. *Endocr J*. 2012; 59:859–866. [PubMed: 22785103]
76. Gibril F, Schumann M, Pace A, et al. Multiple endocrine neoplasia type 1 and Zollinger-Ellison syndrome. A prospective study of 107 cases and comparison with 1009 patients from the literature. *Medicine (Baltimore)*. 2004; 83:43–83. [PubMed: 14747767]
77. Goncalves TD, Toledo RA, Sekiya T, et al. Penetrance of functioning and nonfunctioning pancreatic neuroendocrine tumors in multiple endocrine neoplasia type 1 in the second decade of life. *J Clin Endocrinol Metab*. 2014; 99:E89–E96. [PubMed: 24178797]
78. Agin A, Charrie A, Chikh K, et al. Fast test: clinical practice and interpretation. *Ann Endocrinol (Paris)*. 2013; 74:174–184. [PubMed: 23790314]
79. Cryer PE, Axelrod L, Grossman AB, et al. Diagnostic accuracy of an “amended” insulin-glucose ratio for the biochemical diagnosis of insulinomas. *Ann Intern Med*. 2013; 158:500–501. [PubMed: 23552360]
80. Buffet A, Vezzosi D, Maiza JC, et al. Increased plasma beta-hydroxybutyrate levels during the fasting test in patients with endogenous hyperinsulinaemic hypoglycaemia. *Eur J Endocrinol*. 2013; 169:91–97. [PubMed: 23657581]
81. Guettier JM, Lungu A, Goodling A, et al. The role of proinsulin and insulin in the diagnosis of insulinoma: a critical evaluation of the Endocrine Society clinical practice guideline. *J Clin Endocrinol Metab*. 2013; 98:4752–4758. [PubMed: 24081736]
82. De Leon DD, Stanley CA. Determination of insulin for the diagnosis of hyperinsulinemic hypoglycemia. *Best Pract Res Clin Endocrinol Metab*. 2013; 27:763–769. [PubMed: 24275188]
83. Nauck MA, Meier JJ. Diagnostic accuracy of an “amended” insulin-glucose ratio for the biochemical diagnosis of insulinomas. *Ann Intern Med*. 2012; 157:767–775. [PubMed: 23208166]
84. Cryer PE, Axelrod L, Grossman AB, et al. Evaluation and management of adult hypoglycemic disorders: an Endocrine Society Clinical Practice Guideline. *J Clin Endocrinol Metab*. 2009; 94:709–728. [PubMed: 19088155]
85. Okabayashi T, Shima Y, Sumiyoshi T, et al. Diagnosis and management of insulinoma. *World J Gastroenterol*. 2013; 19:829–837. [PubMed: 23430217]
86. Qiao XW, Qiu L, Chen YJ, et al. Chromogranin A is a reliable serum diagnostic biomarker for pancreatic neuroendocrine tumors but not for insulinomas. *BMC Endocr Disord*. 2014; 14:64. [PubMed: 25099181]
87. Modlin IM, Gustafsson BI, Moss SF, et al. Chromogranin A-Biological Function and Clinical Utility in Neuro Endocrine Tumor Disease. *Ann Surg Oncol*. 2010; 17:2427–2443. [PubMed: 20217257]
88. Sharma P, Arora S, Dhull VS, et al. Evaluation of Ga-DOTANOC PET/CT imaging in a large exclusive population of pancreatic neuroendocrine tumors. *Abdom Imaging*. 2014
89. Sharma P, Arora S, Mukherjee A, et al. Predictive value of 68Ga-DOTANOC PET/CT in patients with suspicion of neuroendocrine tumors: is its routine use justified? *Clin Nucl Med*. 2014; 39:37–43. [PubMed: 24152621]
90. Sharma P, Naswa N, Kc SS, et al. Comparison of the prognostic values of Ga-DOTANOC PET/CT and F-FDG PET/CT in patients with well-differentiated neuroendocrine tumor. *Eur J Nucl Med Mol Imaging*. 2014
91. Treglia G, Castaldi P, Rindi G, et al. Diagnostic performance of Gallium-68 somatostatin receptor PET and PET/CT in patients with thoracic and gastroenteropancreatic neuroendocrine tumours: a meta-analysis. *Endocrine*. 2012; 42:80–87. [PubMed: 22350660]
92. Rufini V, Baum RP, Castaldi P, et al. Role of PET/CT in the functional imaging of endocrine pancreatic tumors. *Abdom Imaging*. 2012; 37:1004–1020. [PubMed: 22422069]
93. Schmid-Tannwald C, Schmid-Tannwald CM, Morelli JN, et al. Comparison of abdominal MRI with diffusion-weighted imaging to 68Ga-DOTATATE PET/CT in detection of neuroendocrine tumors of the pancreas. *Eur J Nucl Med Mol Imaging*. 2013; 40:897–907. [PubMed: 23460395]
94. Etchebehere EC, de Oliveira SA, Gumz B, et al. 68Ga-DOTATATE PET/CT, 99mTc-HYNIC-Octreotide SPECT/CT, and Whole-Body MR Imaging in Detection of Neuroendocrine Tumors: A Prospective Trial. *J Nucl Med*. 2014; 55:1598–1604. [PubMed: 25168627]

95. Wild D, Bomanji JB, Benkert P, et al. Comparison of 68Ga-DOTANOC and 68Ga-DOTATATE PET/CT within patients with gastroenteropancreatic neuroendocrine tumors. *J Nucl Med.* 2013; 54:364–372. [PubMed: 23297077]
96. Ambrosini V, Campana D, Bodei L, et al. 68Ga-DOTANOC PET/CT clinical impact in patients with neuroendocrine tumors. *J Nucl Med.* 2010; 51:669–673. [PubMed: 20395323]
97. Naji M, Al-Nahhas A. (6)(8)Ga-labelled peptides in the management of neuroectodermal tumours. *Eur J Nucl Med Mol Imaging.* 2012; 39(Suppl 1):S61–S67. [PubMed: 22388623]
98. Sharma P, Arora S, Karunanithi S, et al. Somatostatin receptor based PET/CT imaging with 68Ga-DOTA-Nal3-Octreotide for localisation of clinically and biochemically suspected insulinoma. *Q J Nucl Med Mol Imaging.* 2014
99. Sundin A. Radiological and nuclear medicine imaging of gastroenteropancreatic neuroendocrine tumours. *Best Pract Res Clin Gastroenterol.* 2012; 26:803–818. [PubMed: 23582920]
100. Naswa N, Sharma P, Soundararajan R, et al. Diagnostic performance of somatostatin receptor PET/CT using (68)Ga-DOTANOC in gastrinoma patients with negative or equivocal CT findings. *Abdom Imaging.* 2013; 38:552–560. [PubMed: 22743840]
101. Ilhan H, Fendler WP, Cyran CC, et al. Impact of Ga-DOTATATE PET/CT on the Surgical Management of Primary Neuroendocrine Tumors of the Pancreas or Ileum. *Ann Surg Oncol.* 2014
102. Bartsch DK, Waldmann J, Fendrich V, et al. Impact of lymphadenectomy on survival after surgery for sporadic gastrinoma. *Br J Surg.* 2012; 99:1234–1240. [PubMed: 22864882]
103. Lopez CL, Falconi M, Waldmann J, et al. Partial pancreaticoduodenectomy can provide cure for duodenal gastrinoma associated with multiple endocrine neoplasia type 1. *Ann Surg.* 2013; 257:308–314. [PubMed: 22580937]
104. Dickson PV, Rich TA, Xing Y, et al. Achieving eugastrinemia in MEN1 patients: both duodenal inspection and formal lymph node dissection are important. *Surgery.* 2011; 150:1143–1152. [PubMed: 22136834]
105. Ogawa S, Wada M, Fukushima M, et al. Case of primary hepatic gastrinoma: Diagnostic usefulness of the selective arterial calcium injection test. *Hepatol Res.* 2014
106. Naoe H, Iwasaki H, Kawasaki T, et al. Primary hepatic gastrinoma as an unusual manifestation of zollinger-ellison syndrome. *Case Rep Gastroenterol.* 2012; 6:590–595. [PubMed: 23271988]
107. Lu X, Aoun E, Morrissey S. Primary hepatic gastrinoma presenting as vague gastrointestinal symptoms. *BMJ Case Rep (#2012).* 2012; 2012:4.
108. Tonelli F, Giudici F, Nesi G, et al. Biliary tree gastrinomas in multiple endocrine neoplasia type 1 syndrome. *World J Gastroenterol.* 2013; 19:8312–8320. [PubMed: 24363522]
109. Bartsch DK, Albers M, Knoop R, et al. Enucleation and Limited Pancreatic Resection Provide Long-Term Cure for Insulinoma in Multiple Endocrine Neoplasia Type 1. *Neuroendocrinology.* 2014
110. Lewis MA, Thompson GB, Young WF Jr. Preoperative assessment of the pancreas in multiple endocrine neoplasia type 1. *World J Surg.* 2012; 36:1375–1381. [PubMed: 22382771]
111. Naswa N, Sharma P, Kumar A, et al. (6)(8)Ga-DOTANOC PET/CT in patients with carcinoma of unknown primary of neuroendocrine origin. *Clin Nucl Med.* 2012; 37:245–251. [PubMed: 22310250]
112. Grozinsky-Glasberg S, Barak D, Fraenkel M, et al. Peptide receptor radioligand therapy is an effective treatment for the long-term stabilization of malignant gastrinomas. *Cancer.* 2011; 117:1377–1385. [PubMed: 21425137]
113. Frilling A, Sotiropoulos GC, Radtke A, et al. The impact of 68Ga-DOTATOC positron emission tomography/computed tomography on the multimodal management of patients with neuroendocrine tumors. *Ann Surg.* 2010; 252:850–856. [PubMed: 21037441]
114. Binderup T, Knigge U, Loft A, et al. 18F-fluorodeoxyglucose positron emission tomography predicts survival of patients with neuroendocrine tumors. *Clin Cancer Res.* 2010; 16:978–985. [PubMed: 20103666]
115. Barbe C, Murat A, Dupas B, et al. Magnetic resonance imaging versus endoscopic ultrasonography for the detection of pancreatic tumours in multiple endocrine neoplasia type 1. *Dig Liver Dis.* 2012; 44:228–234. [PubMed: 22078814]

116. Semelka RC, Custodio CM, Cem Balci N, et al. Neuroendocrine tumors of the pancreas: spectrum of appearances on MRI. *J Magn Reson Imaging*. 2000; 11:141–148. [PubMed: 10713946]
117. Foti G, Boninsegna L, Falconi M, et al. Preoperative assessment of nonfunctioning pancreatic endocrine tumours: role of MDCT and MRI. *Radiol Med*. 2013; 118:1082–1101. [PubMed: 23801403]
118. Kann PH, Kann B, Fassbender WJ, et al. Small neuroendocrine pancreatic tumors in multiple endocrine neoplasia type 1 (MEN1): least significant change of tumor diameter as determined by endoscopic ultrasound (EUS) imaging. *Exp Clin Endocrinol Diabetes*. 2006; 114:361–365. [PubMed: 16915538]
119. Kann PH, Balakina E, Ivan D, et al. Natural course of small, asymptomatic neuroendocrine pancreatic tumours in multiple endocrine neoplasia type 1: an endoscopic ultrasound imaging study. *Endocr Relat Cancer*. 2006; 13:1195–1202. [PubMed: 17158764]
120. Tseng LM, Chen JY, Won JG, et al. The role of intra-arterial calcium stimulation test with hepatic venous sampling (IACS) in the management of occult insulinomas. *Ann Surg Oncol*. 2007; 14:2121–2127. [PubMed: 17431724]
121. Baba Y, Hayashi S, Senokuchi T, et al. Which indexes are appropriate among those derived from selective arterial calcium stimulation and venous sampling (ASVS) for diagnosing pancreatic insulinomas? Evaluation using receiver operating characteristic analyses. *Pancreas*. 2011; 40:308–310. [PubMed: 21311308]
122. Sowa-Staszczak A, Pach D, Mikolajczak R, et al. Glucagon-like peptide-1 receptor imaging with [Lys40(Ahx-HYNIC- 99mTc/EDDA)NH2]-exendin-4 for the detection of insulinoma. *Eur J Nucl Med Mol Imaging*. 2013; 40:524–531. [PubMed: 23224740]
123. Cases AI, Ohtsuka T, Fujino M, et al. Expression of glucagon-like Peptide 1 receptor and its effects on biologic behavior in pancreatic neuroendocrine tumors. *Pancreas*. 2014; 43:1–6. [PubMed: 24326362]
124. Eriksson O, Velikyan I, Selvaraju RK, et al. Detection of metastatic insulinoma by positron emission tomography with [(68)ga]exendin-4-a case report. *J Clin Endocrinol Metab*. 2014; 99:1519–1524. [PubMed: 24512490]
125. Christ E, Wild D, Forrer F, et al. Glucagon-like peptide-1 receptor imaging for localization of insulinomas. *J Clin Endocrinol Metab*. 2009; 94:4398–4405. [PubMed: 19820010]
126. Braatvedt G, Jennison E, Holdaway IM. Comparison of two low-dose calcium infusion schedules for localization of insulinomas by selective pancreatic arterial injection with hepatic venous sampling for insulin. *Clin Endocrinol (Oxf)*. 2014; 80:80–84. [PubMed: 23711285]
127. Morganstein DL, Lewis DH, Jackson J, et al. The role of arterial stimulation and simultaneous venous sampling in addition to cross-sectional imaging for localisation of biochemically proven insulinoma. *Eur Radiol*. 2009; 19:2467–2473. [PubMed: 19597822]
128. Giudici F, Nesi G, Brandi ML, et al. Surgical management of insulinomas in multiple endocrine neoplasia type 1. *Pancreas*. 2012; 41:547–553. [PubMed: 22228047]
129. Kloppel G. Classification and pathology of gastroenteropancreatic neuroendocrine neoplasms. *Endocr Relat Cancer*. 2011; 18(Suppl 1):S1–S16. [PubMed: 22005112]
130. Rindi, G.; Arnold, R.; Bosman, FT.; Capella, C.; Klimstra, DS.; Kloppel, G.; Komminoth, P.; Solcia, E. Nomenclature and classification of neuroendocrine neoplasms of the digestive system. In: Bosman, FT.; Carneiro, F.; Hruban, RH.; Theise, N., editors. *WHO Classification of Tumors of the Digestive System*. Lyon: IARC Press; 2010. p. 13-14.
131. Strosberg JR, Cheema A, Weber J, et al. Prognostic validity of a novel American Joint Committee on Cancer Staging Classification for pancreatic neuroendocrine tumors. *J Clin Oncol*. 2011; 29:3044–3049. [PubMed: 21709192]
132. Oberg K. The genetics of neuroendocrine tumors. *Semin Oncol*. 2013; 40:37–44. [PubMed: 23391111]
133. Martin-Perez E, Capdevila J, Castellano D, et al. Prognostic factors and long-term outcome of pancreatic neuroendocrine neoplasms: Ki-67 index shows a greater impact on survival than disease stage. The large experience of the Spanish National Tumor Registry (RGETNE). *Neuroendocrinology*. 2013; 98:156–168. [PubMed: 23988576]

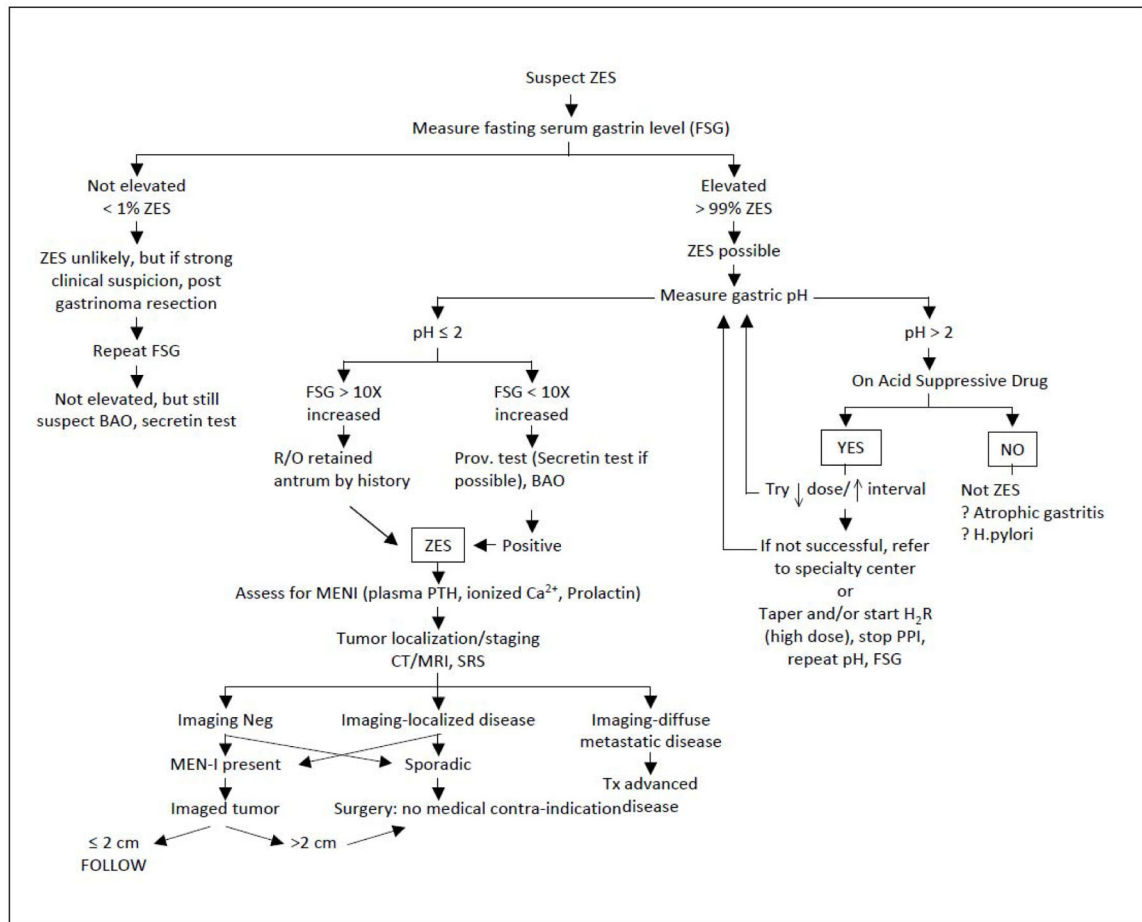
134. Chan JA, Kulke MH. New treatment options for patients with advanced neuroendocrine tumors. *Curr Treat Options Oncol*. 2011; 12:136–148. [PubMed: 21437592]
135. Ito T, Igarashi H, Jensen RT. Therapy of metastatic pancreatic neuroendocrine tumors (pNETs): recent insights and advances. *J Gastroenterol*. 2012; 47:941–960. [PubMed: 22886480]
136. Leung R, Lang B, Wong H, et al. Advances in the systemic treatment of neuroendocrine tumors in the era of molecular therapy. *Anticancer Agents Med Chem*. 2013; 13:382–388. [PubMed: 23092266]
137. Fazio N, Scarpa A, Falconi M. Molecular targeted therapy in enteropancreatic neuroendocrine tumors: from biology to clinical practice. *Curr Med Chem*. 2014; 21:1017–1025. [PubMed: 23992320]
138. Rindi G, Falconi M, Klersy C, et al. TNM Staging of Neoplasms of the Endocrine Pancreas: Results From a Large International Cohort Study. *J Natl Cancer Inst*. 2012; 104:764–777. [PubMed: 22525418]
139. Scarpa A, Mantovani W, Capelli P, et al. Pancreatic endocrine tumors: improved TNM staging and histopathological grading permit a clinically efficient prognostic stratification of patients. *Mod Pathol*. 2010; 23:824–833. [PubMed: 20305616]
140. Oberg K, Knigge U, Kwekkeboom D, et al. Neuroendocrine gastro-entero-pancreatic tumors: ESMO Clinical Practice Guidelines for diagnosis, treatment and follow-up. *Ann Oncol*. 2012; 23(Suppl 7):vii124–vii130. [PubMed: 22997445]
141. Krampitz GW, Norton JA, Poultsides GA, et al. Lymph nodes and survival in duodenal and pancreatic neuroendocrine tumors. *Arch Surg*. 2012; 147:820–827. [PubMed: 22987171]
142. Cao Y, Gao Z, Li L, et al. Whole exome sequencing of insulinoma reveals recurrent T372R mutations in YY1. *Nat Commun*. 2013; 4:2810. [PubMed: 24326773]
143. Zhang L, Lohse CM, Dao LN, et al. Proposed histopathologic grading system derived from a study of KIT and CK19 expression in pancreatic endocrine neoplasm. *Hum Pathol*. 2011; 42:324–331. [PubMed: 21190722]
144. Jiao Y, Shi C, Edil BH, et al. DAXX/ATRX, MEN1, and mTOR pathway genes are frequently altered in pancreatic neuroendocrine tumors. *Science*. 2011; 331:1199–1203. [PubMed: 21252315]
145. de Wilde RF, Edil BH, Hruban RH, et al. Well-differentiated pancreatic neuroendocrine tumors: from genetics to therapy. *Nat Rev Gastroenterol Hepatol*. 2012; 9:199–208. [PubMed: 22310917]
146. Lee HS, Chen M, Kim JH, et al. Analysis of 320 gastroenteropancreatic neuroendocrine tumors identifies TS expression as independent biomarker for survival. *Int J Cancer*. 2014; 135:128–137. [PubMed: 24347111]
147. Agarwal SK, Mateo CM, Marx SJ. Rare germline mutations in cyclin-dependent kinase inhibitor genes in multiple endocrine neoplasia type 1 and related states. *J Clin Endocrinol Metab*. 2009; 94:1826–1834. [PubMed: 19141585]
148. Thakker RV. Multiple endocrine neoplasia type 1 (MEN1) and type 4 (MEN4). *Mol Cell Endocrinol*. 2014; 386:2–15. [PubMed: 23933118]
149. Larghi A, Capurso G, Carnuccio A, et al. Ki-67 grading of nonfunctioning pancreatic neuroendocrine tumors on histologic samples obtained by EUS-guided fine-needle tissue acquisition: a prospective study. *Gastrointest Endosc*. 2012; 76:570–577. [PubMed: 22898415]
150. Schmitt AM, Riniker F, Anlauf M, et al. Islet 1 (Isl1) expression is a reliable marker for pancreatic endocrine tumors and their metastases. *Am J Surg Pathol*. 2008; 32:420–425. [PubMed: 18300808]
151. Sangoi AR, Ohgami RS, Pai RK, et al. PAX8 expression reliably distinguishes pancreatic well-differentiated neuroendocrine tumors from ileal and pulmonary well-differentiated neuroendocrine tumors and pancreatic acinar cell carcinoma. *Mod Pathol*. 2011; 24:412–424. [PubMed: 20890270]
152. Norton JA, Fraker DL, Alexander HR, et al. Value of surgery in patients with negative imaging and sporadic zollinger-ellison syndrome. *Ann Surg*. 2012; 256:509–517. [PubMed: 22868363]
153. Atema JJ, Amri R, Busch OR, et al. Surgical treatment of gastrinomas: a single-centre experience. *HPB (Oxford)*. 2012; 14:833–838. [PubMed: 23134185]



154. Maire F, Sauvanet A, Couvelard A, et al. Recurrence after surgical resection of gastrinoma: who, when, where and why? *Eur J Gastroenterol Hepatol.* 2012; 24:368–374. [PubMed: 22410712]
155. Giovinazzo F, Butturini G, Monsellato D, et al. Lymph nodes metastasis and recurrences justify an aggressive treatment of gastrinoma. *Updates Surg.* 2013; 65:19–24. [PubMed: 23417896]
156. Norton JA, Harris EJ, Chen Y, et al. Pancreatic endocrine tumors with major vascular abutment, involvement, or encasement and indication for resection. *Arch Surg.* 2011; 146:724–732. [PubMed: 21690450]
157. Birnbaum DJ, Turrini O, Vigano L, et al. Surgical Management of Advanced Pancreatic Neuroendocrine Tumors: Short-Term and Long-Term Results from an International Multi-institutional Study. *Ann Surg Oncol.* 2014
158. Birnbaum DJ, Turrini O, Ewald J, et al. Pancreatic neuroendocrine tumor: A multivariate analysis of factors influencing survival. *Eur J Surg Oncol.* 2014
159. Haugvik SP, Labori KJ, Edwin B, et al. Surgical treatment of sporadic pancreatic neuroendocrine tumors: a state of the art review. *Scientific World Journal.* 2012; 2012:357475. [PubMed: 23304085]
160. Haugvik SP, Labori KJ, Waage A, et al. Pancreatic surgery with vascular reconstruction in patients with locally advanced pancreatic neuroendocrine tumors. *J Gastrointest Surg.* 2013; 17:1224–1232. [PubMed: 23670519]
161. Krampitz GW, Norton JA. Current management of the Zollinger-Ellison syndrome. *Adv Surg.* 2013; 47:59–79. [PubMed: 24298844]
162. Imamura M, Komoto I, Ota S, et al. Biochemically curative surgery for gastrinoma in multiple endocrine neoplasia type 1 patients. *World J Gastroenterol.* 2011; 17:1343–1353. [PubMed: 21455335]
163. Kulke MH, Anthony LB, Bushnell DL, et al. NANETS Treatment Guidelines: Well-Differentiated Neuroendocrine Tumors of the Stomach and Pancreas. *Pancreas.* 2010; 39:735–752. [PubMed: 20664472]
164. Peranteau WH, Palladino AA, Bhatti TR, et al. The surgical management of insulinomas in children. *J Pediatr Surg.* 2013; 48:2517–2524. [PubMed: 24314196]
165. Mehrahi A, Fischer L, Hafezi M, et al. A systematic review of localization, surgical treatment options, and outcome of insulinoma. *Pancreas.* 2014; 43:675–686. [PubMed: 24921202]
166. Guo Q, Wu Y. Surgical treatment of pancreatic islet cell tumor: report of 44 cases. *Hepatogastroenterology.* 2013; 60:2099–2102. [PubMed: 24719954]
167. Knigge U, Hansen CP. Surgery for GEP-NETs. *Best Pract Res Clin Gastroenterol.* 2012; 26:819–831. [PubMed: 23582921]
168. Su AP, Ke NW, Zhang Y, et al. Is laparoscopic approach for pancreatic insulinomas safe? Results of a systematic review and meta-analysis. *J Surg Res.* 2014; 186:126–134. [PubMed: 23992857]
169. Sciuto A, Abete R, Reggio S, et al. Laparoscopic spleen-preserving distal pancreatectomy for insulinoma: experience of a single center. *Int J Surg.* 2014; 12(Suppl 1):S152–S155. [PubMed: 24862672]
170. Fernandez-Cruz L, Martinez I, Cesar-Borges G, et al. Laparoscopic surgery in patients with sporadic and multiple insulinomas associated with multiple endocrine neoplasia type 1. *J Gastrointest Surg.* 2005; 9:381–388. [PubMed: 15749601]
171. Al-Kurd A, Chapchay K, Grozinsky-Glasberg S, et al. Laparoscopic resection of pancreatic neuroendocrine tumors. *World J Gastroenterol.* 2014; 20:4908–4916. [PubMed: 24803802]
172. Fernandez-Cruz L, Blanco L, Cosa R, et al. Is laparoscopic resection adequate in patients with neuroendocrine pancreatic tumors? *World J Surg.* 2008; 32:904–917. [PubMed: 18264824]
173. Haugvik SP, Marangos IP, Rosok BI, et al. Long-term outcome of laparoscopic surgery for pancreatic neuroendocrine tumors. *World J Surg.* 2013; 37:582–590. [PubMed: 23263686]
174. Cheema A, Weber J, Strosberg JR. Incidental detection of pancreatic neuroendocrine tumors: an analysis of incidence and outcomes. *Ann Surg Oncol.* 2012; 19:2932–2936. [PubMed: 22350605]
175. Gaujoux S, Partelli S, Maire F, et al. Observational study of natural history of small sporadic nonfunctioning pancreatic neuroendocrine tumors. *J Clin Endocrinol Metab.* 2013; 98:4784–4789. [PubMed: 24057286]

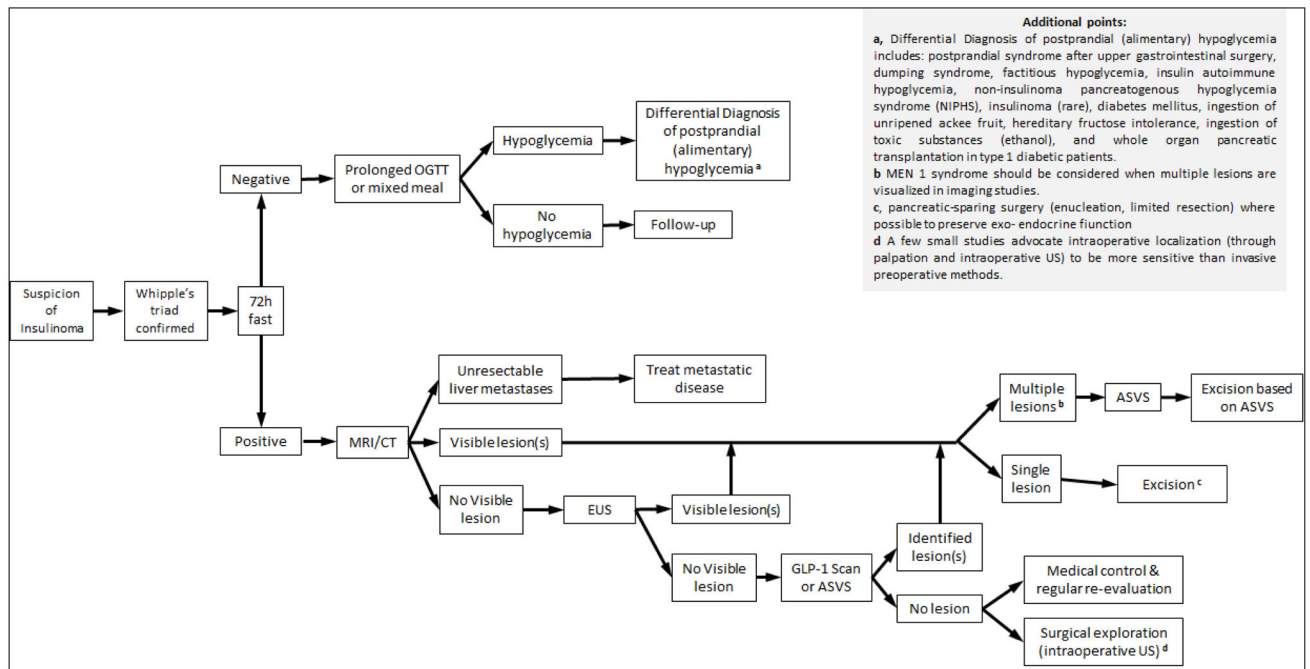
176. de Mestier L, Gaujoux S, Cros J, et al. Long-term Prognosis of Resected Pancreatic Neuroendocrine Tumors in von Hippel-Lindau Disease Is Favorable and Not Influenced by Small Tumors Left in Place. *Ann Surg*. 2014
177. Gaujoux S, Gonen M, Tang L, et al. Synchronous resection of primary and liver metastases for neuroendocrine tumors. *Ann Surg Oncol*. 2012; 19:4270–4277. [PubMed: 22752376]
178. Ito T, Jensen RT. Association of long-term proton pump inhibitor therapy with bone fractures and effects on absorption of calcium, vitamin b(12), iron, and magnesium. *Curr Gastroenterol Rep*. 2010; 12:448–457. [PubMed: 20882439]
179. Luk CP, Parsons R, Lee YP, et al. Proton pump inhibitor-associated hypomagnesemia: what do FDA data tell us? *Ann Pharmacother*. 2013; 47:773–780. [PubMed: 23632281]
180. Corleto VD, Festa S, Di Giulio E, et al. Proton pump inhibitor therapy and potential long-term harm. *Curr Opin Endocrinol Diabetes Obes*. 2014; 21:3–8. [PubMed: 24310148]
181. Famularo G, Gasbarrone L, Minisola G. Hypomagnesemia and proton-pump inhibitors. *Expert Opin Drug Saf*. 2013; 12:709–716. [PubMed: 23808631]
182. Reimer C. Safety of long-term PPI therapy. *Best Pract Res Clin Gastroenterol*. 2013; 27:443–454. [PubMed: 23998981]
183. Heidelbaugh JJ, Metz DC, Yang YX. Proton pump inhibitors: are they overutilised in clinical practice and do they pose significant risk? *Int J Clin Pract*. 2012; 66:582–591. [PubMed: 22607510]
184. Vakil N. Prescribing proton pump inhibitors: is it time to pause and rethink? *Drugs*. 2012; 72:437–445. [PubMed: 22356286]
185. Ojeaburu JV, Ito T, Crafa P, et al. Mechanism of Acid hypersecretion post curative gastrinoma resection. *Dig Dis Sci*. 2011; 56:139–154. [PubMed: 20725788]
186. Tabarin A, Goichot B. Treatment: symptomatic treatment of hypoglycaemia. *Ann Endocrinol (Paris)*. 2013; 74:196–199. [PubMed: 23791453]
187. Baudin E, Caron P, Lombard-Bohas C, et al. Malignant insulinoma: recommendations for characterisation and treatment. *Ann Endocrinol (Paris)*. 2013; 74:523–533. [PubMed: 23993836]
188. Ferrer-Garcia JC, Iranzo Gonzalez-Cruz V, Navas-DeSolis S, et al. Management of malignant insulinoma. *Clin Transl Oncol*. 2013; 15:725–731. [PubMed: 23460559]
189. Jawiarczyk A, Bolanowski M, Strycka J, et al. Effective therapy of insulinoma by using long-acting somatostatin analogue. A case report and literature review. *Exp Clin Endocrinol Diabetes*. 2012; 120:68–72. [PubMed: 22187292]
190. Oberg KE, Reubi JC, Kwekkeboom DJ, et al. Role of somatostatins in gastroenteropancreatic neuroendocrine tumor development and therapy. *Gastroenterology*. 2010; 139:742–53. 753. [PubMed: 20637207]
191. Bernard V, Lombard-Bohas C, Taquet MC, et al. Efficacy of everolimus in patients with metastatic insulinoma and refractory hypoglycemia. *Eur J Endocrinol*. 2013; 168:665–674. [PubMed: 23392213]
192. Chen J, Wang C, Han J, et al. Therapeutic effect of sunitinib malate and its influence on blood glucose concentrations in a patient with metastatic insulinoma. *Expert Rev Anticancer Ther*. 2013; 13:737–743. [PubMed: 23573816]
193. Maiza JC, Vezzosi D, Grunenwald S, et al. Treatment with somatostatin analogs and chemoembolization of liver metastases for severe hypoglycemia in malignant insulinomas. *J Endocrinol Invest*. 2011; 34:e253–e258. [PubMed: 21623151]
194. de Herder WW, van Schaik E, Kwekkeboom D, et al. New therapeutic options for metastatic malignant insulinomas. *Clin Endocrinol (Oxf)*. 2011; 75:277–284. [PubMed: 21649688]
195. van Schaik E, van Vliet EI, Feelders RA, et al. Improved control of severe hypoglycemia in patients with malignant insulinomas by Peptide receptor radionuclide therapy. *J Clin Endocrinol Metab*. 2011; 96:3381–3389. [PubMed: 21917872]
196. Ghazi AA, Amirbaigloo A, Dezfooli AA, et al. Ectopic acromegaly due to growth hormone releasing hormone. *Endocrine*. 2013; 43:293–302. [PubMed: 22983831]
197. Eldor R, Glaser B, Fraenkel M, et al. Glucagonoma and the glucagonoma syndrome - cumulative experience with an elusive endocrine tumour. *Clin Endocrinol (Oxf)*. 2011; 74:593–598. [PubMed: 21470282]

198. Baldelli R, Barnabei A, Rizza L, et al. Somatostatin Analogs Therapy in Gastroenteropancreatic Neuroendocrine Tumors: Current Aspects and New Perspectives. *Front Endocrinol (Lausanne)*. 2014; 5:7. [PubMed: 24570674]
199. Imhof A, Brunner P, Marincek N, et al. Response, survival, and long-term toxicity after therapy with the radiolabeled somatostatin analogue [90Y-DOTA]-TOC in metastasized neuroendocrine cancers. *J Clin Oncol*. 2011; 29:2416–2423. [PubMed: 21555692]
200. Kwekkeboom DJ, de Herder WW, Kam BL, et al. Treatment with the radiolabeled somatostatin analog [177 Lu-DOTA 0,Tyr3]octreotate: toxicity, efficacy, and survival. *J Clin Oncol*. 2008; 26:2124–2130. [PubMed: 18445841]
201. Kwekkeboom DJ, Kam BL, Van Essen M, et al. Somatostatin-receptor-based imaging and therapy of gastroenteropancreatic neuroendocrine tumors. *Endocr Relat Cancer*. 2010; 17:R53–R73. [PubMed: 19995807]
202. Bushnell DL Jr, O’Dorisio TM, O’Dorisio MS, et al. 90Y-edotreotide for metastatic carcinoid refractory to octreotide. *J Clin Oncol*. 2010; 28:1652–1659. [PubMed: 20194865]
203. Bodei L, Mueller-Brand J, Baum RP, et al. The joint IAEA, EANM, and SNMMI practical guidance on peptide receptor radionuclide therapy (PRRNT) in neuroendocrine tumours. *Eur J Nucl Med Mol Imaging*. 2013; 40:800–816. [PubMed: 23389427]
204. Kwekkeboom DJ, Krenning EP, Scheidhauer K, et al. ENETS Consensus Guidelines for the Standards of Care in Neuroendocrine Tumors: somatostatin receptor imaging with (111)In-pentetreotide. *Neuroendocrinology*. 2009; 90:184–189. [PubMed: 19713709]
205. Delle Fave GF, O’Toole D, Sundin A, Taal B, Ferolla P, Ramage J, Ferone D, Ito T, Weber W, Zheng-Pei Z, De Herder WW, Pascher A, Ruzsniwski P. all other Vienna Consensus Conference participants. Consensus guidelines update for gastroduodenal neuroendocrine neoplasms. *Neuroendocrinology*. 10.1159/000443168
206. Niederle B, Pape UF, Costa F, Gross D, Kelestimir F, Knigge U, Öberg K, Pavel M, Perren A, Toumpanakis C, O’Connor J, O’Toole D, Krenning E, Reed N, Kianmanesh R. all other Vienna Consensus Conference participants. Consensus guidelines update for neuroendocrine neoplasm of the jejunum and ileum. *Neuroendocrinology*. 10.1159/000443170
207. Ramage J, De Herder WW, Delle Fave GF, Ferolla P, Ferone D, Ito T, Ruzsniwski P, Sundin A, Weber W, Zheng-Pei Z, Taal B, Pascher A. all other Vienna Consensus Conference participants. Consensus guidelines update for colorectal neuroendocrine neoplasms (NEN). *Neuroendocrinology*. 10.1159/000443166
208. Pape UF, Niederle B, Costa F, Gross D, Kelestimir F, Kianmanesh R, Knigge U, Öberg K, Pavel M, Perren A, Toumpanakis C, O’Connor J, Krenning E, Reed N, O’Toole D. all other Vienna Consensus Conference participants. Consensus guidelines for neuroendocrine neoplasms of the appendix (excluding goblet cell carcinomas). *Neuroendocrinology*. 10.1159/000443165
209. Pavel M, O’Toole D, Costa F, Capdevila J, Gross D, Kianmanesh R, Krenning E, Knigge U, Salazar R, Pape UF, Öberg K. all other Vienna Consensus Conference participants. Consensus guidelines update for the management of distant metastatic disease of intestinal, pancreatic, bronchial neuroendocrine neoplasms (NEN) and NEN of unknown primary site. *Neuroendocrinology*. 10.1159/000443167
210. Garcia-Carbonero R, Sorbye H, Baudin E, Raymond E, Wiedenmann B, Niederle B, Sedlackova E, Toumpanakis C, Anlauf M, Cwikla J, Caplin M, O’Toole D, Perren A. all other Vienna Consensus Conference participants. Consensus guidelines for high grade gastro-entero-pancreatic (GEP) neuroendocrine tumours and neuroendocrine carcinomas (NEC). *Neuroendocrinology*. 10.1159/000443172



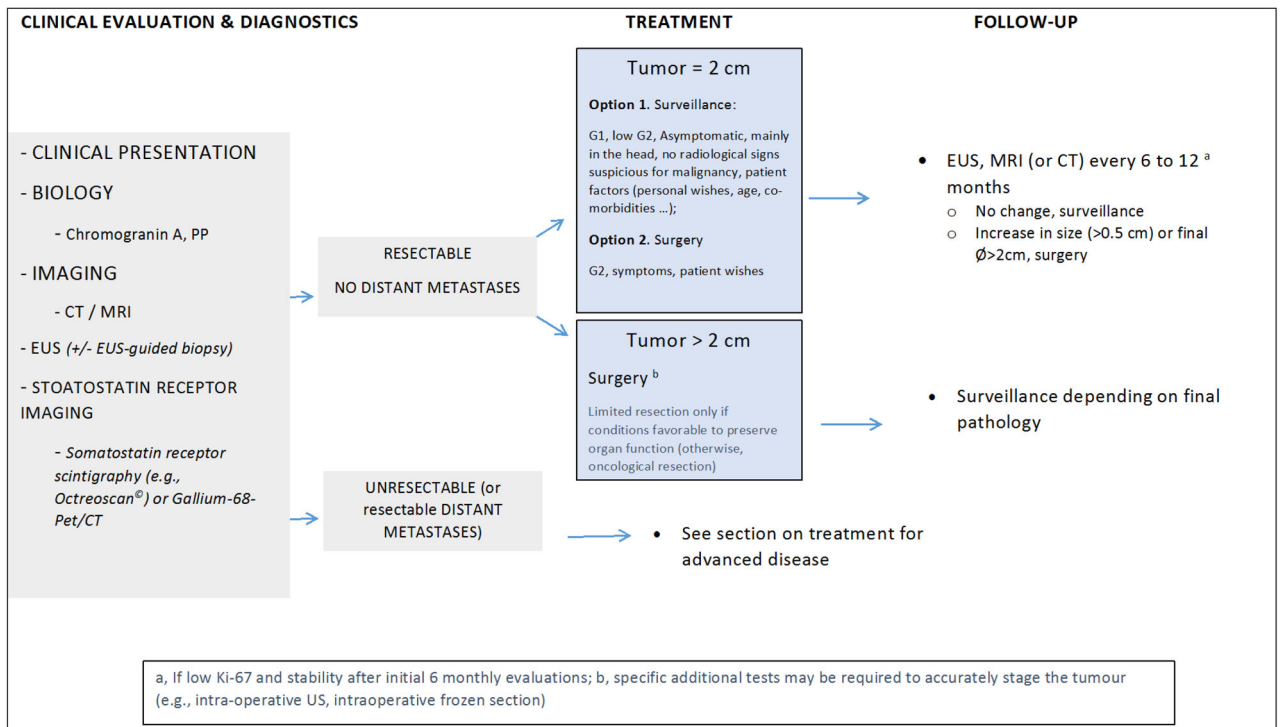
**Figure 1. Suspicion of Zollinger-Ellison syndrome (ZES)**

ZES: Zollinger-Ellison syndrome; FSG: fasting serum gastrin; BAO: basal acid output; MEN1: multiple endocrine neoplasia type 1; PPI: proton pump inhibitor; H<sub>2</sub>RA: H<sub>2</sub> receptor antagonist.



**Figure 2. Suspicion of insulinoma**

OGTT: oral glucose tolerance test; MRI: magnetic resonance imaging, CT: computerized tomography, EUS: endoscopic ultrasound; ASVS: arterial stimulation venous sampling; GLP-1: glucagon-like peptide 1; US: ultrasound



**Figure 3.**  
Algorithm for treating nonfunctioning pancreatic neuroendocrine neoplasms

Table 1

## Functional Pancreatic endocrine tumors [F-p-NET] syndromes

Name	Biologically Active Peptide(s) Secreted	Incidence (new cases/10 <sup>6</sup> population/yr)	Tumor Location	Malignant (%)	Associated with MEN-1 (%)	Main Symptoms/Signs
<b>A. Most common Functional Pancreatic Endocrine Tumor syndromes</b>						
Insulinoma	Insulin	1 – 32	Pancreas (>99%)	<10	4 – 5	Hypoglycemic symptoms (100%)
Zollinger-Ellison Syndrome	Gastrin	0.5 – 21.5	Duodenum (70%) Pancreas (25%) Other sites (5%)	60 – 90	20 – 25	Pain (79–100%) Diarrhea (30–75%) Esophageal symptoms (31–56%)
<b>B. Established Rare functional Pancreatic Endocrine Tumor syndromes [RFTS](&gt;100 cases)</b>						
VIPoma (Verner–Morrison Syndrome, Pancreatic cholera, WDHA)	Vasoactive intestinal pPeptide	0.05 – 0.2	Pancreas (90%, adult) Other - (10%, neural, adrenal, periganglionic)	40 – 70	6	Diarrhea (90–100%) Hypokalemic (80–100%) Dehydration (83%)
Glucagonoma	Glucagon	0.01 – 0.1	Pancreas (100%)	50 – 80	1 – 20	Rash (67–90%) Glucose intolerance (38–87%) Weight loss (66–96%)
Somatostatinoma	Somatostatin	Rare	Pancreas (55%) Duodenum/Jejunum (44%)	>70	45	Diabetes mellitus (63–90%) Cholelithiasis (65–90%) Diarrhea (35–90%)
GRHoma	Growth hormone-releasing hormone	Unknown	Pancreas (30%) Lung (54%) Jejunum (7%) Other (13%)	>60	16	Acromegaly (100%)
ACTHoma	ACTH	Rare	Pancreas (4–16% all Ectopic Cushing's)	>95	Rare	Cushing's syndrome (100%)
P-NET causing carcinoid syndrome	Serotonin ? Tachykinins	Rare (43 cases)	Pancreas (<1% all carcinoids)	60 – 88	Rare	Same as carcinoid syndrome above
P-NET causing hypercalcemia (PTHrp-oma)	PTHrpP Others unknown	Rare	Pancreas (rare cause of hypercalcemia)	84	Rare	Abdominal pain due to hepatic metastases
<b>II. Very Rare Functional p-NET Syndromes(1–5 cases)</b>						
P-NET secreting renin	renin	Rare	Pancreas	Unknown	No	Hypertension
P-NET secreting luteinizing Luteinizing-hormone	Luteinizing hormone	Rare	Pancreas	Unknown	No	Anovulation, virilization(female); reduced libido (male)
p-NET secreting erythropoietin	Erythropoietin	Rare	Pancreas	100	No	polycythemia
p-NET secreting IF-II	Insulin-like growth factor II	Rare	Pancreas	Unknown	No	Hypoglycemia

<b>Name</b>	<b>Biologically Active Peptide(s) Secreted</b>	<b>Incidence (new cases/10<sup>6</sup> population/yr)</b>	<b>Tumor Location</b>	<b>Malignant (%)</b>	<b>Associated with MEN-1 (%)</b>	<b>Main Symptoms/Signs</b>
p-NET secreting CCK(CC Koma)	CCK	Rare	Pancreas	unknown	no	Diarrhea, ulcer disease, Weight loss, cholelithiasis
...p-NET secreting GLP-1	GLP-1 Hypoglycemia	Rare	Pancreas	unknown	no	no

GLP-1, glucagon like peptide 1; VIP, vasoactive intestinal peptide; WDHA, watery diarrhea, hypokalemia, achlorhydria; CCK, cholecystokinin; PTH-rP, parathyroid hormone related peptide; IG-2, insulin like growth factor 2; p-NET, pancreatic neuroendocrine tumor;